

Coronary Artery Ectasia on an Undiagnosed Rheumatoid Arthritis Female Patient: Case Report and Literature Review

Dr .Rihab Machtache ; Dr .Sara Chibane ; Dr Amal Moukhliiss
Dr Salim Arous ; Pr Ghali Bennouna ; Pr leila Azzouzi ; Pr Rachida Habbal

*Correspondent Author: Dr Machtache rihab
Department of cardiology
IBN ROCHD University Teaching Hospital
Hassan II University - casablanca -MOROCCO

Abstract

➤ Background

Coronary artery ectasia or CAE is defined as an inappropriate diffuse or localized non obstructive lesions of an epicardial coronary artery with a luminal dilatation more than the largest diameter of normal vessel more than diameter 1.5-fold [1.2.3.17.27].

Rheumatoid diseases are due to an immune inflammation may touch several systems with frequent cardiovascular consequences may include perimyocarditis, valvular diseases, coronary artery disease, and even heart failure more or less preserved ejection fraction, pulmonary hypertension, aneurysms and thrombosis. [4]

➤ Materials / Methods

We report here a case of a 61 year old moroccan female poor followed patient with hypertension, who was admitted to our hospital with acute coronary syndrome and has shown diffuse CAE (coronary arteries ectasia) of the three vessels TYPE I of Markis Classification. The rheumatoid arthritis was suspected and diagnosed during hospitalization and the treatment began.

➤ Findings

Even Arthritis (RA) is defined as a chronic, inflammatory, autoimmune disease, with unknown etiology, beside an insidious joint damage, leading to limited activities for the majority of. Furthermore, RA can be responsible of systemic complications and early mortality [18.28]. Rarely, the RA is diagnosed after cardiac complications.

The coronary CT angiography was performed and revealed significant diffused coronary artery ectasia interesting the three vessels classified TYPE I of Markis Classification secondary to late diagnosis of rheumatoid arthritis [19].

➤ Conclusions

Atherosclerosis is considered as the principal etiology for more than 50% of coronary arteries ectasia adult cases[2.15]. Certainly Rheumatoid arthritis (RA) is a common inflammatory auto- immune disorder of the joints that affects almost 1% of the population and affects apart from synovial extra articular tissues such as vasculitis, lung disease, and cardiac complications, which include among other pericarditis, myocarditis, valvular affection, ischemic heart disease including coronary artery ectasia and heart failure.

Keywords:- Coronary Artery Ectasia; Rheumatoid Polyarthritis; Acute Coronary Syndrome; Case Report.

I. INTRODUCTION

RA patients have a reduced life expectancy essentially due to increased cardiovascular morbidity in comparison to the general population [5.20.21] and the majority of deaths are secondary to cardiovascular diseases (CVD) [6.20]. Traditional CVD factors like hypertension, sedentary, the resistance of insulin, body alterations, and dyslipidemia [7.21]. The high systemic inflammation, RA disease particularities, interfere with the common factors and may also contribute to the increase CVD morbidity and mortality [8.21].

II. CASE PRESENTATION

Here we present a 61 years old poorly followed female patient, admitted to our institution with acute chest pain since 5h. She has been known only hypertensive. The ECG (Electrocardiogram) realized showed a non ST segment elevation with an acute coronary syndrome. A coronary angiography (CAG) was realized the same day and showed diffuse ectasia of coronary arteries interesting the three vessels classified TYPE I of Markis classification without thrombus (FIG 1, FIG2, FIG 3). The rheumatoid arthritis was suspected and diagnosed during hospitalization and the treatment started.

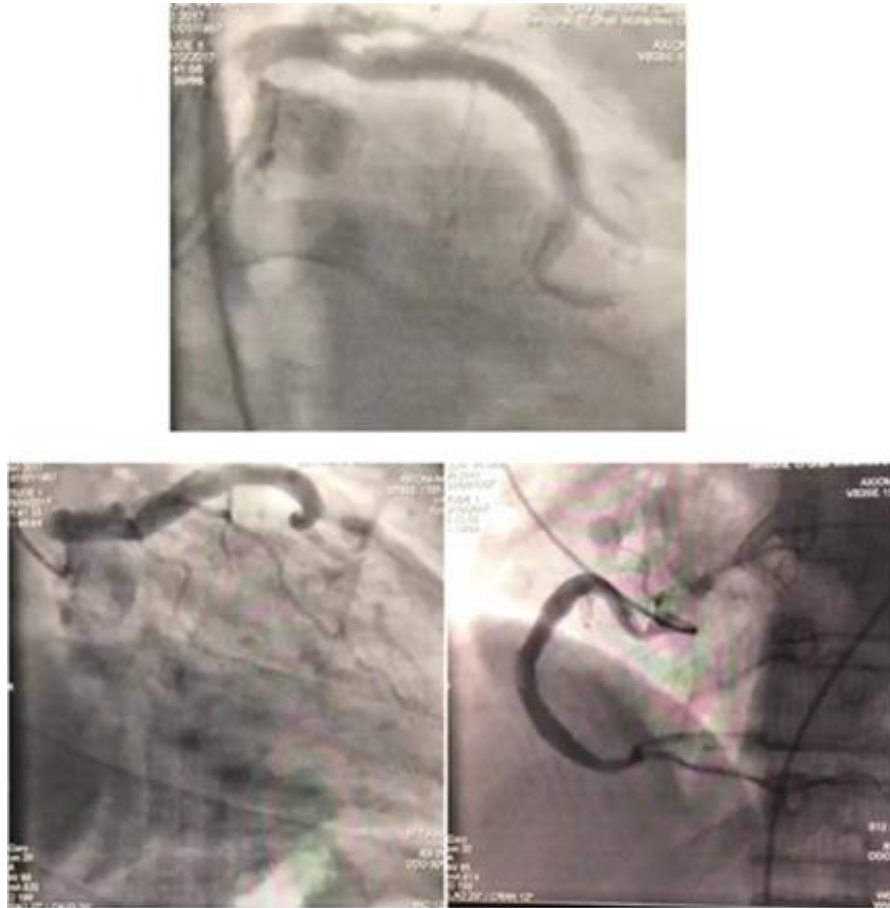


Fig 1, 2, 3:- Coronary Artery Ectasia

III. DISCUSSION

Rheumatoid Arthritis (RA) is known as a chronic, inflammatory, autoimmune disorder with symmetric peripheral polyarthritis, whose etiology is unknown, associated with progressive joint dysfunction, leading to functional limitation for patient's daily activities. It can cause systemic complications and eventual early mortality. [18].

The Chronic inflammation causes polyarticular joint damage. The incidence is highest between 25 and 55 years old and decreases after 75 years old [9.22].

Pathologically, vascular ectasia and atherosclerosis are very similar. Arterial lumen can be reduced, preserved or dilated parallel to the atherosclerosis progression. While atherosclerosis causes vessel lumen reducing, the mechanism of luminal dilatation is not very clear. Thanks to a phenomenon of arterial remodeling, some plaques do not reduce considerably the vascular lumina because of a phenomenon of vascular expansion [15.23].

During the atherosclerosis progression, the expansion is the mainly compensatory phenomenon for preserving the vascular size. CAE may be secondary to the increasing of the external elastic membrane and the luminal size too [15.16.23].

The onset of rheumatoid arthritis may be preceded by extra-articular manifestations. Mortality from RA is due to several complications such as ischemic heart disease and infection which are the most common causes of death [10.22].

Coronary artery disease is the mainly cause of death in patients with RA [11.22]. Patients with RA are at increased risk for silent myocardial infarction. [12.24].

Almost 20–30% of cases of coronary ectasia are congenital. Of the acquired cases, 50% are associated with atherosclerosis while 10%–20% occur with inflammation and infection [13.24.25].

The symptomatology of patients with isolated CAE varies widely and can include typical or atypical angina or even myocardial infarction [14.24.25]. Coronary artery ectasia may interest all three vessels but in 75% cases it affects a single artery [15]. Markis classified CAE in four types: the type 1 includes diffuse ectasia involving two or three vessels, the type 2 includes diffuse ectasia in one vessel and discrete ectasia in another vessel, the type 3 includes diffuse ectasia in only one vessel, and type 4 which includes localized or segmental ectasia in only one vessel [24.25].

IV. CONCLUSION

Nowadays, rheumatoid arthritis is a common disease which is evaluated and managed. Its complications are not well known. This disease can affect several vital organs, including the cardiovascular one, [22].

Patients suffering from rheumatoid arthritis (RA) have a high risk of mortality, largely attributed to increased cardiovascular (CV) death[26].

➤ *Interest Conflict*
None

BIBLIOGRAPHY

- [1]. G.G. Hartnell, B.M. Parnell, R.B. Pridie, Coronary artery ectasia. Its prevalence and clinical significance in 4993 patients, *British Heart Journal* 54 (4) (1985) 392–395.
- [2]. M. Syed, M. Lesch, Coronary artery aneurysm: a review, *Progress in Cardiovascular Diseases* 40 (1) (1997) 77–84.
- [3]. Giannoglou GD, Antoniadis AP, Chatzizisis YS, Damvopoulou GE, Parcharidis GE, Louridas GE. Prevalence of ectasia in human coronary arteries in patients in northern Greece referred for coronary angiography. *Am J Cardiol* 2006;98:314–8.
- [4]. Ignatios Ikonomidis, MD, PHD, a George Makavos, MD, PHD, a Pelagia Katsimbri, MD, PHD, b Dimitrios T. Boumpas, MD, PHD, b John Parissis, MD, PHD, a Efstathios Iliodromitis, MD, PHD a]. *Imaging Risk in Multisystem Inflammatory Diseases (J Am Coll Cardiol Img 2019;:—) © 2019 by the American College of Cardiology Foundation.*
- [5]. Kitas GD, Erb N. Tackling ischaemic heart disease in rheumatoid arthritis. *Rheumatology (Oxford)* 2003;42(5):607–13.
- [6]. Aviaña-Zubietta JA, Choi HK, Sadatsafavi M, Etminan M, Esdaile J M, Lacaille D. Risk of cardiovascular mortality in patients with rheumatoid arthritis: a meta-analysis of observational studies. *Arthritis Rheum* 2008;59:1690–7.
- [7]. del Rincón ID, Williams K, Stern MP, Freeman GL, Escalante A. High incidence of cardiovascular events in rheumatoid arthritis cohort not explained by traditional cardiac risk factors. *Arthritis Rheum* 2001;44:2737–45.
- [8]. Mavrogeni S, Spargias K, Markussis V, Kolovou G, Demerouti E, Papadopoulou E, et al. Myocardial inflammation in autoimmune diseases: investigation by cardiovascular magnetic resonance and endomyocardial biopsy. *Inflamm Allergy Drug Targets* 2009;8:390–7.
- [9]. Kasper DL, Fauci AS, Hauser SL, Longo DL, Jameson JL, Loscalzo J, eds. *Harrison's manual of medicine*. 19th edn. New York: McGraw-Hill Education; 2016.
- [10]. Tintinalli JE, Stapczynski JS, American College of Emergency Physicians. *Tintinalli's emergency medicine: a comprehensive study guide*. 7th edn. New York: McGraw-Hill Medical; 2011.
- [11]. Tocci G, Goletti D, Marino V, et al. Cardiovascular outcomes and tumour necrosis factor antagonists in chronic inflammatory rheumatic disease: a focus on rheumatoid arthritis. *Expert Opin Drug Saf* 2016;15(suppl 1):55–61.
- [12]. G.A. Karpouzas, J. Malpeso, T.Y. Choi, D. Li, S. Munoz, M.J. Budoff. Prevalence, extent and composition of coronary plaque in patients with rheumatoid arthritis without symptoms or prior diagnosis of coronary artery disease. *Ann Rheum Dis*, 73 (10) (2014), pp. 1797-1804
- [13]. Sultana R, Sultana N, Ishaq M, et al. The prevalence and clinical profile of angiographic coronary ectasia. *J Pak Med Assoc*. 2011;61(4):372–375
- [14]. Krüger D, Stierle U, Herrmann G, et al. Exercise-induced myocardial ischemia in isolated coronary artery ectasias and aneurysms ('dilated coronopathy'). *J Am Coll Cardiol*. 1999;34:1461–1470
- [15]. P. Schoenhagen, K.M. Ziada, D.G. Vince, et al., Arterial remodeling and coronary artery disease: the concept of dilated versus obstructive coronary atherosclerosis, *Journal of the American College of Cardiology* 38 (2) (2001) 297
- [16]. Y.S. Chatzizisis, A.U. Coskun, M. Jonas, et al., Role of endothelial shear stress in the natural history of coronary atherosclerosis and vascular remodeling: molecular, cellular, and vascular behavior, *Journal of the American College of Cardiology* 49 (25) (2007) 2379–2393.
- [17]. Eid Mohamed Daoud, Ayman Ahmed Abdelaziz, Nahed Abdallah Hassan. "Isolated coronary artery ectasia debate: Inflammation versus atherosclerosis", *The Egyptian Heart Journal*, 2012
- [18]. Ramão Souza de Deus Junior, Andressa Leite, Ferraz, Silvia Aparecida Oesterreich, Wanderlei Onofre Schmitz et al. "Risk factors for cardiovascular disease in rheumatoid arthritis patients from Mato Grosso do Sul", *Revista Brasileira de Reumatologia (English Edition)*, 2015
- [19]. Al Salihi, S., E. Jacobi, R. Hunter, and M. Buja. "Multiple giant coronary artery aneurysms: a case report", *Cardiovascular Pathology*, 2016.
- [20]. Mavrogeni, Sophie, Theodoros Dimitroulas, Petros P. Sfikakis, and George D. Kitas. "Heart involvement in rheumatoid arthritis: Multimodality imaging and the emerging role of cardiac magnetic resonance", *Seminars in Arthritis and Rheumatism*, 2013.
- [21]. Sophie Mavrogeni, Theodoros Dimitroulas, Petros P. Sfikakis, George D. Kitas. "Heart involvement in rheumatoid arthritis: Multimodality imaging and the emerging role of cardiac magnetic resonance", *Seminars in Arthritis and Rheumatism*, 2013
- [22]. Samantha Berman, Joshua Bucher, Alex Koefman, Brit J. Long. "Emergent Complications of Rheumatoid Arthritis", *The Journal of Emergency Medicine*, 2018

- [23]. Aldons J.Lusis Nature.2000 Sep 14 ;407 (6801) :233-241.
- [24]. Brian G.Kral, Lewis C.Becker, Dhananjay Vaidya,Lisa R.Yanek,Diane M.Becker Silent myocardial ischaemia and long-term coronary artery disease outcomes in apparently healthy people from families with early-onset ischaemic heart disease 2011 Nov; 32(22):2766-2772
- [25]. Amit Malviya, Pravin K. Jha, Animesh Mishra."Isolated coronary artery ectasia: Clinical, angiographic, and follow up characteristics", Indian Heart Journal, 2017
- [26]. Arnon Blum,Mohammad Adawi."Rheumatoid arthritis (RA) and cardiovascular disease" ,Autoimmunity Reviews, 2019
- [27]. Ertan Yetkin, Johannes Waltenberger. "Novel insights into an old controversy", Clinical Research in Cardiology, 2007
- [28]. Ramão Souza de Deus Junior, Andressa Leite Ferraz, Silvia Aparecida Oesterreich, Wanderlei Onofre Schmitz et al. "Risk factors for cardiovascular disease in rheumatoid arthriti patients from Mato Grosso do Sul", Revista Brasileira de Reumatologia (English Edition), 2015