

# Treatment of Infrabony Defects with Platelet-Rich Fibrin: Case Report

Dr. Raju Anarthe  
Professor at Department of  
Periodontology,  
Pravara Rural Dental College and  
Hospital, Loni

Dr. Amit Mani  
Professor and Head of Department of  
Periodontology,  
Pravara Rural Dental College and  
Hospital, Loni

Dr. Preeti Prakash Kale  
Lecturer at Department of  
Periodontology,  
Pravara Rural Dental College and  
Hospital, Loni

Dr. Rachita Mustilwar  
Lecturer at Department of Periodontology  
Pravara Rural Dental College and Hospital, Loni

Dr. Shriram Kendre  
2nd year Post Graduate Student at  
Department of Periodontology,  
Pravara Rural Dental College and Hospital, Loni

**Abstract:-** Periodontal regeneration is defined as the reproduction or reconstitution of a lost or injured part to restore the architecture and function of the periodontium. The goal of periodontal therapy is to regenerate the destructed periodontal tissue by periodontitis. Efforts to achieve periodontal regeneration in intrabony defect has been achieved using various types of bone grafts. Platelet Rich Fibrin is autologous preparation which is considered as second-generation platelet concentrate consisting of viable platelet releasing different types of growth factors. It is found to be clinically effective and economical for use. This case report presents the clinical and radiographical effectiveness of autologous Platelet rich Fibrin in treatment of intrabony defect.

**Keywords:-** Intrabony Defect, PRF, Regeneration.

## I. INTRODUCTION

Periodontal regeneration is defined as the reproduction or reconstitution of a lost or injured part to restore the architecture and function of the periodontium. The goal of periodontal therapy is to regenerate the destructed periodontal tissue by periodontitis. [1] This regeneration is multifactorial process which requires dependent sequence of biological events which includes cell migration, cell adhesion, proliferation, and cellular differentiation. [2] The second-generation Platelet rich Fibrin was developed by Choukroun et al in France which is being used extensively to accelerate soft and hard tissue healing. It is strictly autologous fibrin matrix which contains large number of leukocyte cytokines and platelets. Carroll et al. [3] in 2005 conducted a study that demonstrated the platelets from platelet rich fibrin which were viable released six different growth factors like platelet derived growth factor (PDGF), Vascular endothelial growth factor, TGF i.e transforming growth factor, IGF i.e insulin like growth factor, epidermal growth factor and Fibroblast growth factor for about 7 days during study duration. As per position paper published from American Academy of Periodontology various periodontal regeneration techniques for treatment of osseous, furcation, and recession defects includes bone grafts, root biomodification, various soft

tissue grafts and combination above all. [4] The periodontal regeneration in intrabony defect around teeth has been previously achieved successfully with the use of various bone grafts available. Various beneficial effects using second generation platelet concentrate has been studied in different clinical applications like facial plastic surgery [5], in maxillary sinus lift procedure during dental implant placement as a sole osteoconductive filling material, and gingival recession cases treated with PRF and coronally advanced flap. [6],[7] Considering that platelet rich fibrin enhances the healing potential of hard and soft tissues. Here 6 – month follow up report of an intrabony defect treated using autologous PRF by assessing clinical and radiological parameters is presented below.

## II. CASE REPORT

Female patient 35years old reported complaining of bleeding gums since 5-6 months to Department of Periodontology of Rural Dental College, Loni, Dist. Ahmednagar, Maharashtra. No relevant medical history and no significant past dental history and no adverse habit was reported by patient.

**Intra-Oral Examination:** Clinical examination revealed presence of generalized bleeding on probing (BOP), generalised gingival inflammation, halitosis, average pocket probing depth was around 6mm to 7mm with clinical attachment level 7 mm as marginal gingiva was at Cemento-Enamel Junction (CEJ). Increased spacing was seen in between 11 and 12 suggestive of pathological migration. (FIGURE 1)

**Radiographic investigation:** A digital OPG revealed presence of generalised horizontal bone loss and interdental angular bone loss on mesial aspect of 47,37,17,15. Intra oral Periapical -radiograph was taken using the standardized technique which showed angular defect on mesial aspect of 47. Based on all above findings diagnosis for the case was Generalised Chronic Periodontitis (AAP 1999, Consensus Report). (FIGURE 2)

A comprehensive treatment plan was formulated based on the clinical examination and radiographic examination with the following sequential steps:

- **Emergency Phase:** Vitality test was performed with tooth no. 47,17,15. Tooth was non-vital, hence access opening was performed with 47,15,17.
- **Etiotrophic Phase:** Patient motivation and oral hygiene instructions with proper homecare was adviced to patient. Non-surgical periodontal therapy was performed. Mouthrinse with 0.2 % CHX twice daily for 7 days was adviced to patient. Re-evaluation after 4 weeks of Phase I therapy showed reduction in inflammatory signs with average probing depth and CAL of 6 mm, hence indicated for periodontal surgery. (FIGURE 3)
- **Surgical Phase:** Obturation was completed with 47,17,15. Surgical periodontal therapy consisted of Kirkland flap surgery with 41 to 47, with placement of PRF in the intrabony defect on mesial aspect of 47. (FIGURE 4-7) Kirkland flap surgery from 31 to 37, 21 to 27, 12 to 17, papilla preservation flap with 11, 12 was also performed.

**Surgical Phase:** Extra-oral antisepsis was carried out using Iodine solution whereas intra-oral antisepsis with 0.2% chlorhexidine digluconate rinse was performed. After the administration of local anesthetic, buccal, lingual sulcular and interdental incisions were made with number - 15 blade and full thickness muco-periosteal flap was reflected with periosteal elevator from tooth 41 to 48. (FIGURE 4)

10ml sterile syringe was used to collect intravenous blood from the patient which was immediately centrifuged at 1600 RPM for 12 min. PRF consisting of fibrin clot in between red corpuscles at bottom and acellular plasma i.e. platelet poor plasma at the top was obtained in the test tube which was subjected to centrifugation (FIGURE 5). Meticulous debridement of intrabony defect on mesial aspect of 47 was carried out and scaling and root planing done along with presuturing with 3.0 non absorbable silk suture. Platelet rich fibrin obtained was filled into the intrabony defect and furcation area of 46 (FIGURE 6). The mucoperiosteal flaps elevated were repositioned and secured in place using simple interrupted 3-0 non-absorbable silk surgical suture. The operated area was then covered using periodontal dressing. (FIGURE 7)

**Post-Operative Care :** Periodontal dressing and suture removal was done after 10 days, surgical site was gently cleaned and irrigated with betadine iodine and normal saline solution. Charters brushing technique was reinforced in the region of surgical site. Patient was evaluated at the end of 1month,3month, 6 months. (FIGURE 8) No Periodontal probing was done during this period. Patient was re examined after 6 months of periodontal surgery which showed reduction in pocket probing depth upto 3mm, which was initaially 6mm and CAL from 7mm to 3mm.. (FIGURE 9) no signs of BOP i.e. bleeding on probing were seen. Also significant radiographic bone formation was visible in intrabony defect with mesial aspect of 47. (FIGURE 10)

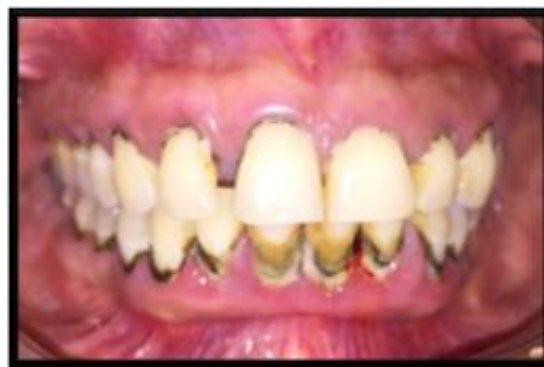

Fig 1:- Preoperative Intraoral View

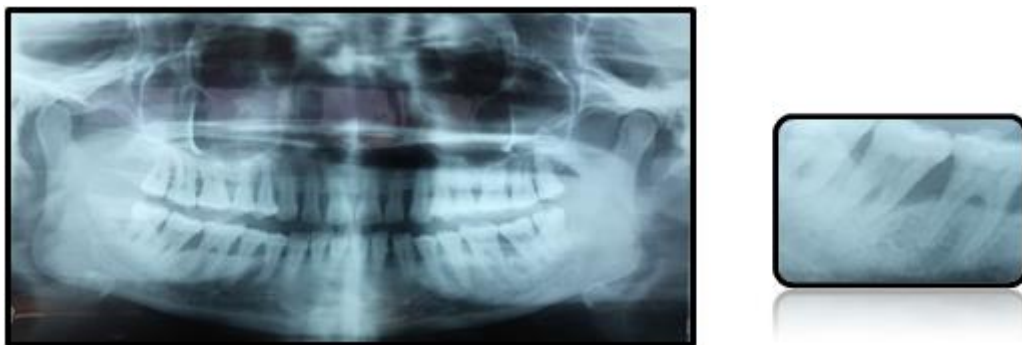

Fig 2:- Preoperative OPG & Preoperative IOPA C 47

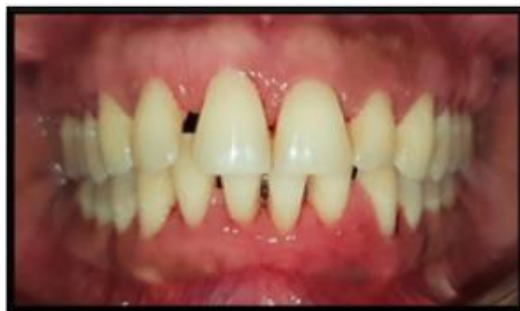

Fig 3:- 1 Week Intraoral View After Srp

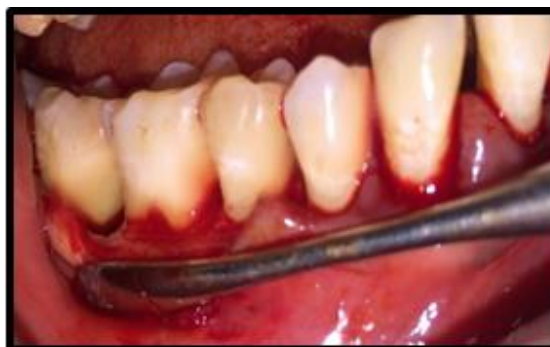

Fig 4:- Full Thickness Mucoperiosteal Flap Reflection With 42-47



Fig 5:- Platelet Rich Fibrin Preparation

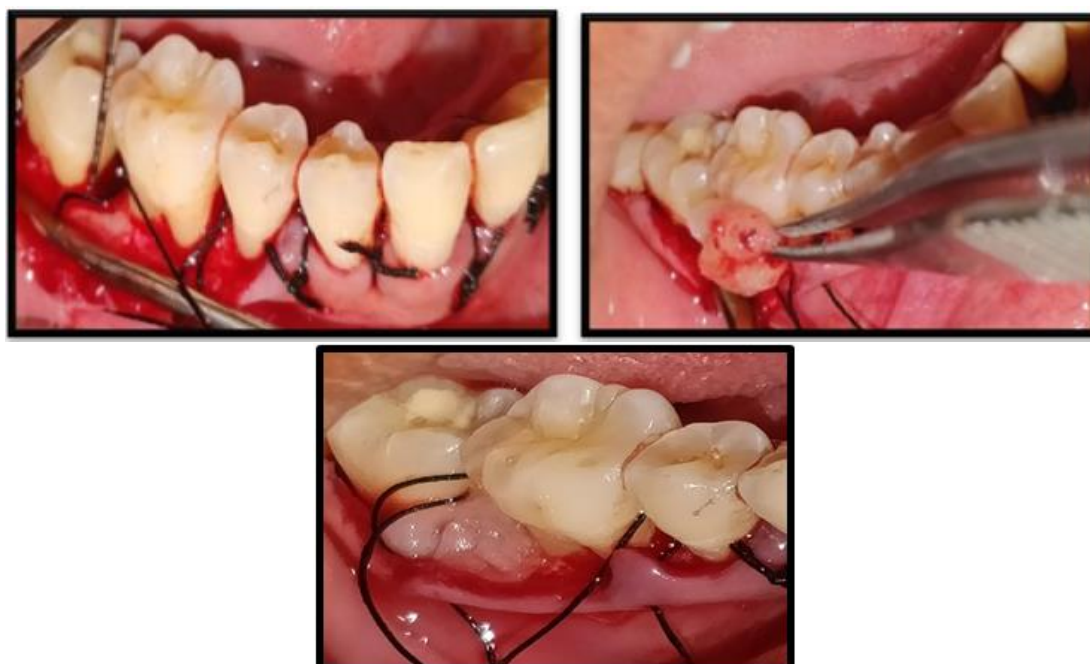

Fig 6:- Presuturing and Placement of PRF in Intrabony Defect

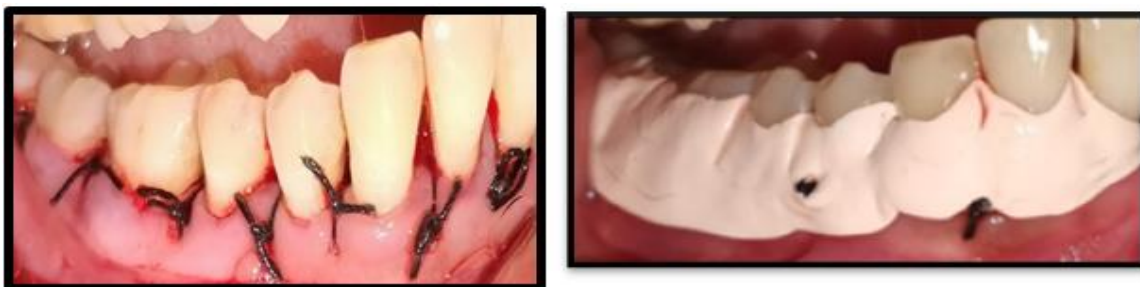

Fig 7:- Sutures in Place and Periodontal Dressing Given.

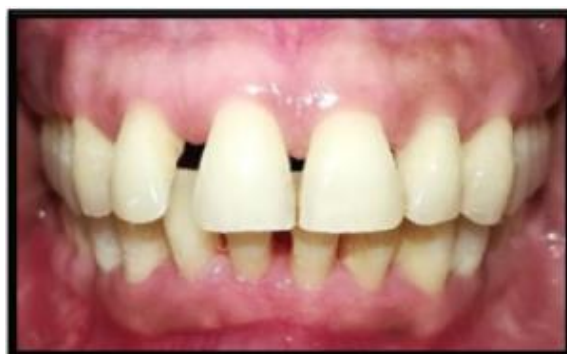

Fig 8:- Postoperative Intraoral View After 6 Months

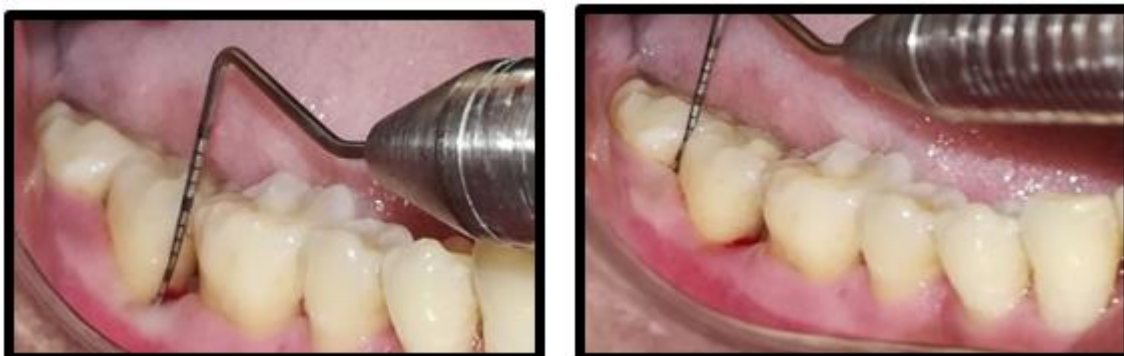

Fig 9:- Postoperative Probing Depth Assesment.

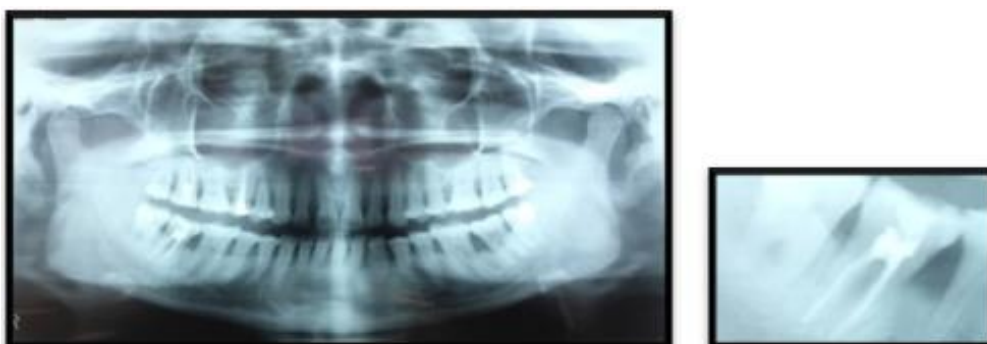


Fig 10:- Postoperative OPG and IOPA C 47.

### III. DISCUSSION

The above case report evaluated the clinical efficacy of platelet rich fibrin in the treatment of intrabony defect with 47. Reduction in pocket probing depth (PPD) and gain in clinical attachment level are the major clinical outcome measured to determine success of any periodontal treatment. Platelet Rich Fibrin by Choukran's technique is

prepared naturally without addition of any artificial thrombin and it is hypothesized that, PRF has a natural fibrin framework which can protect growth factors from proteolysis. Owing to its dense fibrin network matrix, PRF takes longer to be resorbed by the host, which results in slower and sustained release of platelets and leukocyte derived growth factors in to surgical area.<sup>[8], [9]</sup>

Platelet rich fibrin improves osseous defect healing as increase in phosphorylated extracellular signal regulated protein kinase expression and suppress the osteoclastogenesis by promoting secretion of osteoprotegerin in osteoclast cultures <sup>[10]</sup>.

#### IV. CONCLUSION

Platelet rich fibrin using Choukrouns technique is simple and less expensive technique which is useful for successful regeneration of periodontal tissue. Important advantage of using platelet rich fibrin is that it utilises patients own blood which helps in reducing or eliminating disease transmission through blood. More studies and clinical trials are required in future to investigate potential applications of platelet rich field in the field of periodontal regeneration and tissue engineering and to extend its clinical applications in future.

#### REFERENCES

- [1]. Froum SJ, Gomez C, Breault MR. Current concepts of periodontal regeneration. A review of the literature. N Y State Dent J 2002; 68:14-22.
- [2]. Khiste SV, Naik Tari R. Platelet-rich fibrin as a biofuel for tissue regeneration. ISRN Biomaterials. 2013;1-6.
- [3]. Carroll RJ, Amoczky SP, Graham S, O'Connell SM. Characterization of autologous growth factors in Cascade platelet rich fibrin matrix (PRFM). Edison, NJ: Musculoskeletal Transplant Foundation; 2005.
- [4]. Greenwell H; Committee on Research, Science and Therapy. American Academy of Periodontology. Position paper: Guidelines for periodontal therapy. J Periodontol 2001; 72:1624-8.
- [5]. Charrier JB, Monteil JP, Albert S, Collon S, Bobin S, Dohan Ehrenfest DM. Relevance of Choukroun's platelet-rich fibrin (PRF) and SMAS flap in primary reconstruction after superficial or subtotal parotidectomy in patients with focal pleiomorphic adenoma: A new technique. Rev Laryngol Otol Rhinol (Bord) 2008; 129:313-318.
- [6]. Mazor Z, Horowitz RA, Del Corso M, Prasad HS, Rohrer MD, Dohan Ehrenfest DM. Sinus floor augmentation with simultaneous implant placement using Choukroun's platelet-rich fibrin as the sole grafting material: A radiologic and histologic study at 6 months. J Periodontol 2009; 80:2056-2064.
- [7]. Aroca S, Keglevich T, Barbieri B, Gera I, Etienne D. Clinical evaluation of a modified coronally advanced flap alone or in combination with a platelet-rich fibrin membrane for the treatment of adjacent multiple gingival recessions: A 6-month study. J Periodontol 2009; 80:244-252.
- [8]. Dohan DM, Choukroun J, Diss A, et al. Platelet-rich fibrin (PRF): A second-generation platelet concentrate. Part II: Platelet-related biologic features. Oral Surg Oral Med Oral Pathol Oral Radiol Endod 2006;101: e45-e50.

- [9]. Dohan DM, Choukroun J, Diss A, Dohan SL, Dohan AJ, Mouhyi J, et al. Platelet-rich fibrin (PRF): A second-generation platelet concentrate. Part III: Leucocyte activation: A new feature for platelet concentrates? Oral Surg Oral Med Oral Pathol Oral Radiol Endod. 2006;101 :e51–5.
- [10]. Huang FM, Yang SF, Zhao JH, Chang YC. Platelet-rich fibrin increases proliferation and differentiation of human dental pulp cells. J Endod. 2010; 36:1628–32.