

# Left Ethmoidal Polyp Mimicking a Left Antral Mucous Retention Cyst

Ezeike CI

Department of Radiology, Alex-Ekwueme Federal University Teaching Hospital Abakaliki (AE-FUTHA), Ebonyi State, Nigeria.

**Abstract:-** Sinonasal polyps are commonly associated with chronic sinusitis. Prompt and early diagnosis is essential because of the burden of this disease on the patient. This disease negatively affects the quality of life of the patients. Sinonasal polyp should be suspected in patients with chronic sinusitis that is recalcitrant to medical therapy especially in resource-poor centers where endoscopy is not readily available. I present a case of recalcitrant chronic rhinosinusitis with a left ethmoidal polyp which was seen on paranasal sinus computed tomography as a left antral mucous retention cyst. Intraoperative findings showed a polyp arising from the left ethmoidal sinus, extending into the left antrum, mimicking a left antral mucous retention cyst.

**Keywords:-** Left Ethmoidal Polyp, Mucous Retention Cyst, Paranasal Sinus, Chronic Sinusitis.

## I. INTRODUCTION

A nasal polyp is an oedematous non-neoplastic nasal or sinus mucosal mass. The mass is due to fibroedematous infiltration of the subepithelial tissue which is characterized by submucosal extracellular oedema[1].

Ethmoidal sinus polyps constitute a major subtype of the sinonasal polyps. Three to 21 cells are enclosed as a complex labyrinth within the ethmoidal sinus. Polyps may arise from these cell linings or from the uncinat process, middle turbinate, bulla ethmoidalis, and sinus ostia[2].

The exact cause of sinonasal polyp is not clearly understood. However, allergy has been implicated in the majority of patients with polyps[3]. Other authors linked polyps to infections and the Bernoulli effect[4].

The unique structures of the nose are believed to significantly play a role in the formation of sinonasal polyps. Messerklinger et al. postulated that disruption of the mucociliary clearance occurred in any place where two mucosae were in direct contact which leads to infection and inflammation[5]. The narrow cleft of the ethmoids and middle nasal meatus are areas of mucosa contact and has been said to be the most common places from which nasal polyps. The inferior nasal turbinate is not usually considered to be a site of origin of nasal polyps.

Polyps are also associated with the following conditions: asthma, cystic fibrosis, aspirin hypersensitivity, Kartagener's Syndrome, Churg-Strauss Syndrome, Youngs Syndrome, and Nasal Mastocytosis[6].

Ethmoidal polyps are commonly seen in adults[7]. The clinical symptoms include nasal stuffiness, nasal obstruction, sneezing, watery anosmia, nasal discharge, hyposmia, postnasal drip, and hyponasal voice.

Clinical examination may reveal smooth shining pale mass with no tenderness or bleeding with probing. Alar cartilages may be flared with nose broadening and increased intercanthal distance.

Diagnosis is usually clinical. Paranasal sinus radiography, computed tomography (CT) and endoscopy are also very useful. Treatment can be medical or surgical. Medical therapy includes oral steroids, steroid sprays, and antihistamines. The surgical options include simple polypectomy, ethmoidectomy (intranasal or external), and functional endoscopic sinus surgery (FESS)[8].

An ethmoidal polyp may reoccur after surgery. Histology typically shows an oedematous respiratory epithelium. It may also show eosinophilia or squamous metaplasia[9]. I present a case of Left Ethmoidal polyp presenting as a left maxillary mucous retention cyst and bilateral sinusitis

## II. CASE REPORT

Mrs. UJ was a 60-year-old farmer, a Christian from Ezzagu town, in Ishielu local government area of Ebonyi State Nigeria. She presented in 2017 with recurrent right nasal blockage 4 years.

The blockage was initially unilateral and intermittent but later became persistent and bilateral. There was associated intermittent mucopurulent and foul-smelling nasal discharge. There was no epistaxis, however, she had postnasal drip. There was no history of trauma to the nose or head injury. No facial pain, no paraesthesia, no proptosis or retro-orbital pain. Her Vision was intact. No dental pain, no looseness of teeth, no previous tooth extraction. She had no persistent headaches, no loss of consciousness or altered sensorium and no weakness of any part of the body. Her hearing was normal,

with no tinnitus, vertigo, otorrhoea or otalgia. No throat pain including dysphagia, odynophagia or foreign body sensation in the throat. Her voice was normal and there was no breathing difficulty.

The patient did not consume alcohol or tobacco in any form, no exposure to wood dust, nickel or asbestos. She was not a known hypertensive, diabetic or known patient of peptic ulcer disease. She did not have any documented drug allergy. On Examination, there was mucopurulent exudate from the nasal cavity and an engorged left inferior nasal turbinate. Plain radiography of the paranasal sinuses showed opacification of both maxillary antra with air-fluid interphase. The patient subsequently had bilateral antral washout and symptoms abated. The patient, however, failed to keep her follow up appointments.

In 2018, the patient re-presented with bilateral nasal discharge, nasal blockage, mouth breathing, and snoring. Examination revealed bilateral engorged turbinates with a pale cystic mass which was insensitive to touch and no contact bleeding. She was requested to do a computed tomography (CT) scan of paranasal sinuses, which could not be done due to financial constraints. She was again lost to follow up.

In 2019 patient presented again with severe snoring, sleep apnoea, and persistent generalized headache. Examination revealed that both nasal cavities were patent, no bulge noted on the palate. The posterior pharyngeal wall was granular. The patient was finally able to do a CT paranasal sinuses which showed a fairly oval isodense lesion with a superior convex margin noted at the floor of the left antrum extending into the left nasal cavity and nasopharynx with complete obliteration of the ipsilateral ethmoidal sinus. There was also mucosal thickening of the right antrum and an osteoma at the right fronto-ethmoidal sinus junction.

In the absence of FESS, the patient was worked up and had left lateral rhinotomy and medial maxillectomy. Intra-operative findings revealed a polypoid yellowish mass with thick stalk arising from the left ethmoid, transversing the left antrum and just jutting via the left choana. Also noted was the dehiscent left antral wall and thinned right antral medial wall.

The patient did well immediately post-surgery and was discharged on the fourth postoperative day. She attended her first post-operative follow up a week later and has been doing well. Her histology report showed eosinophilia.

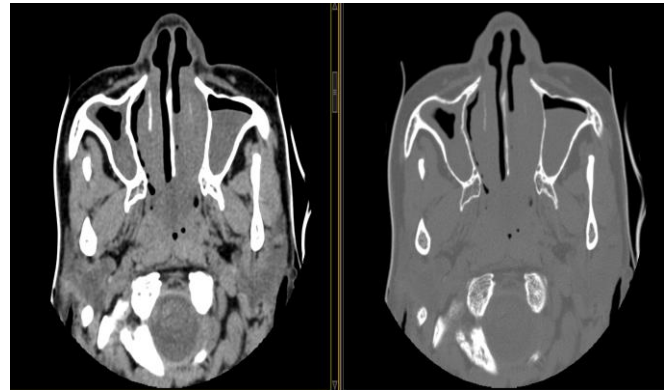


Fig 1: Axial CT of the antra showing mucosal thickening of the right antrum, an isodense lesion in the inferior two-third of the left antrum and enlarged nasal turbinates.

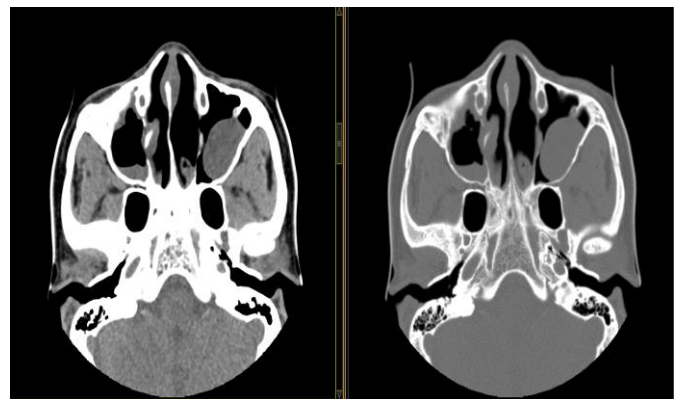


Fig 2: Axial CT of the antra showing an oval isodense lesion in the left antrum with a convex superior margin with no bony erosion. Mucosal thickening of the right antrum is also noted.

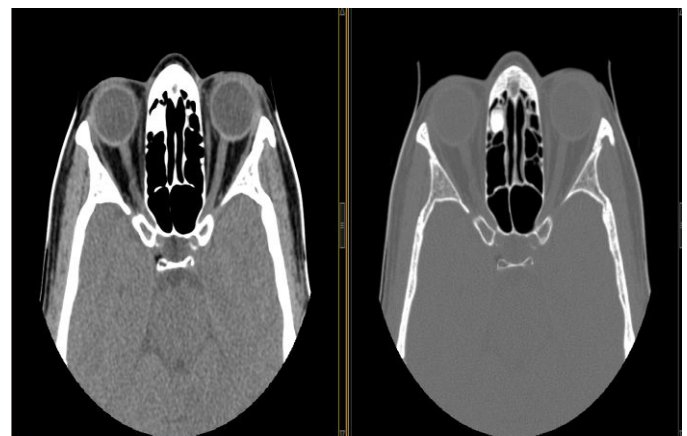


Fig 3: Axial CT at the level of the orbit showing an osteoma of the right ethmoidal sinus

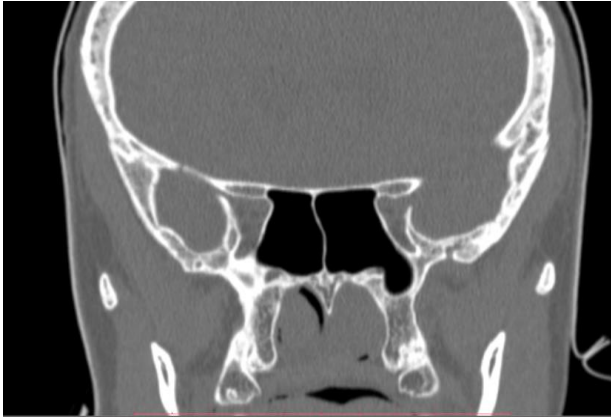


Fig 4: Coronal reconstructed CT of the paranasal sinus showing a near-complete obliteration of the nasal cavities.

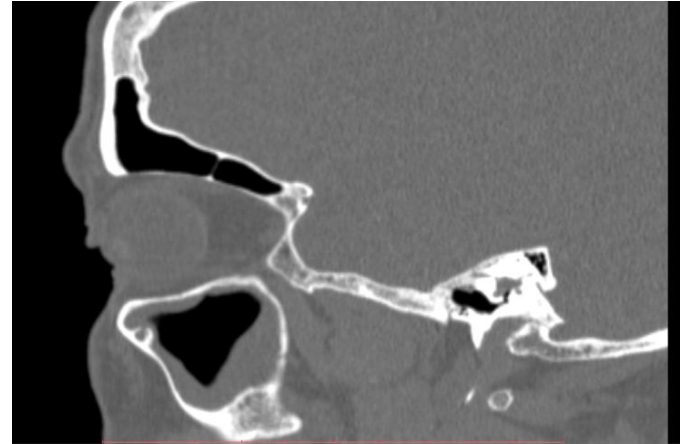


Fig 7: Sagittal reformatted CT of the left antrum showing mucosal thickening.

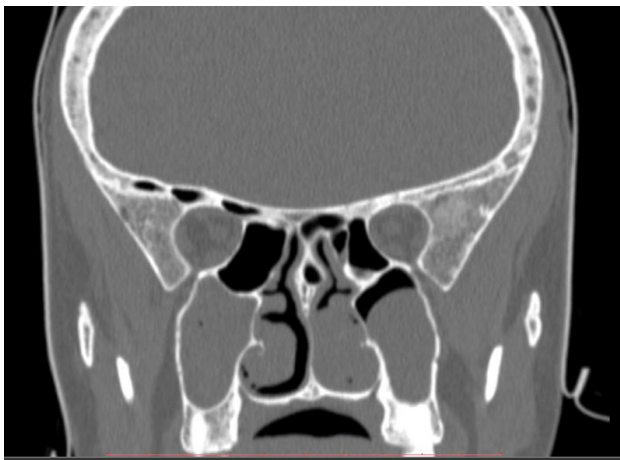


Fig 5: Coronal reformatted CT of the paranasal sinus showing an isodense lesion completely obliterating the right antrum. A similar lesion is noted in the left antrum with a superior convex margin. Enlarged inferior nasal turbinates are also noted.

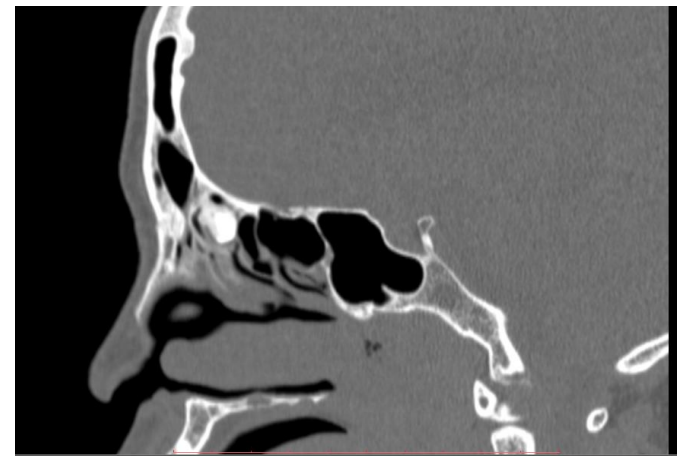

Fig 8: Sagittal reformatted CT of the paranasal sinus showing an osteoma of the ethmoidal sinus

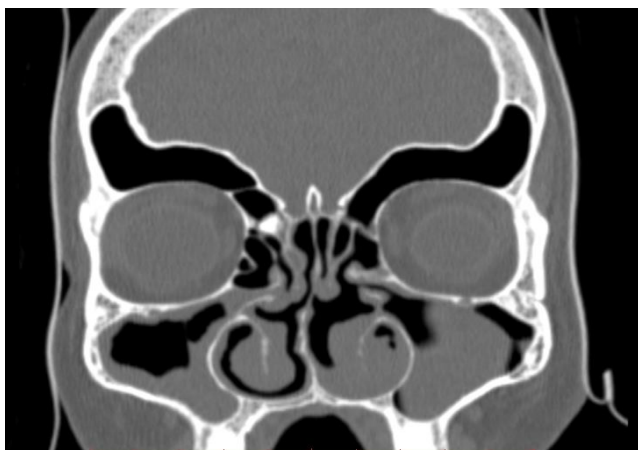


Fig 6: Coronal reconstructed CT of the paranasal sinus showing an osteoma at the left fronto-ethmoidal sinus junction. Left antral mucosal thickening and an isodense right antral lesion are noted.

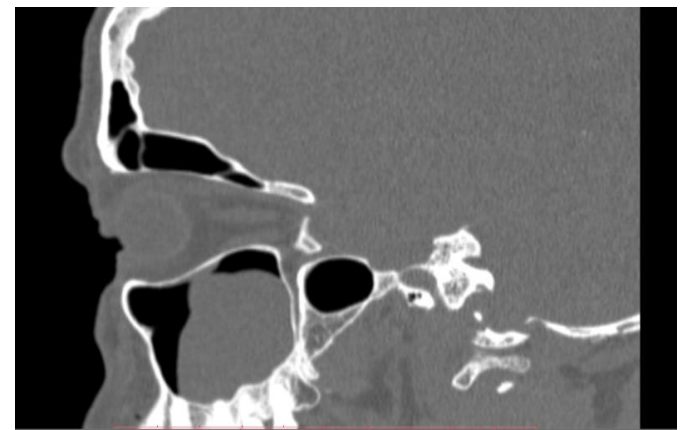


Fig 7: Sagittal reformatted CT of the right antrum showing an oval isodense lesion with a superior convex margin and no obvious bony erosion.



### III. DISCUSSION

Nasal polyp is among the common mass lesions of the nasal cavity and was first described about 4000 years ago in ancient Egypt[10]. It is usually a pale, smooth, gelatinous and semi-translucent nasal mucosal outgrowth or mass. It can, however, be pink in colour if it has a rich blood supply. It usually consists of inflammatory tissues with very low malignant potential[11].

Historically, it has been described in ancient Egypt as 'grapes coming down from the nose'[12]. Ni-Ankh Sekhmet (an ancient Egyptian rhinologist) treated King Sahura's nostrils disease for sinonasal polyps. Sinonasal polyps have not been without controversy since the ancient days. In 1951, Forestus[13] documented that nasal polyps resulted from carrying heavy goods on the head. Paget[10] considered sinonasal polyps as fibrocellular tumors in 1854 while in 1863 Virchow[10] considered them as a type of myxoma. In 1882, Zuckerkandl[10] documented that the majority of sinonasal polyps originated from the middle meatus around the edges of the hiatus semilunaris.

Local epidemiological data among Nigerians are not readily available. Among the Caucasians, the prevalence varies from 1% to 4.3%[14][15] with a male-female ratio of 1.2 to 3[15]. The peak age of incidence is at 50 to 60 years old[16] It is very rare in children except in children with asthma and cystic fibrosis[17].

In Finland, Hedman et al.[14] reported 4.3%, Johansson et al.[15] found 2.7% in Sweden with males to females was 2.2:1. In Korea, Min et al.[18] reported 0.5%,

According to Lanza et al.[19] sinusitis can be defined as inflammation of the paranasal sinuses, nasal cavity, and of the fluid within these cavities and/or the underlying bone. Sinusitis can be grouped into acute, recurrent, subacute and chronic sinusitis.

In 1995, Adams et al.[20] found that 15% of Americans under 45 years old had symptoms of chronic sinusitis. The estimated prevalence rate in Europe varies from 10% to 40%[21][22].

Sinusitis is commoner in children because they tend to have more upper airway infection. Gordts et al.[23] reported that sinusitis was an incidental finding in 45% of children that had magnetic resonance images (MRI).

Nasal polyps and chronic sinusitis are multi-factor diseases and are associated with many other diseases. Chronic sinusitis (8 to 12 weeks of disease duration or more) is one of the common diseases that can co-exist with sinonasal polyp[16]. It occurs in 65% to 90% of patients with sinonasal polyps[24].

Apart from history and physical examination, the diagnosis of sinonasal polyps and chronic sinusitis should be aided by endoscopy, CT, MRI. One study reported that up to 42.5% of cranial CT found paranasal sinus pathology (most common finding was mucosal thickening) as an incidental finding in patients with no paranasal sinus symptoms[25]. Paranasal sinus CT was very instrumental in the index case.

The symptoms of chronic sinusitis with sinonasal polyp are nonspecific. They include nasal congestion, rhinorrhea, drainage, fever, facial pain, headache, a reduced sense of smell, dental pain, cough and otologic symptoms[25]. The index case had nasal congestion with intermittent mucopurulent and foul-smelling nasal discharge. She also had postnasal drip.

Paranasal sinus CT scan is very useful in assessing structural abnormalities, the extent and severity of the disease in addition to other coexisting diseases. This may be very important for sinus surgery however there is no strong correlation between CT findings and symptoms[26].

Using the criteria for the Task Force on Rhinosinusitis (TRF) Hwang et al.[26] reported that only 70 out of 115 patients that met the TRF criteria had a positive CT scanning result while 9 in 10 patients, who did not meet TRF criteria also had a positive CT scans.

Lund et al.[27] in 1995 developed a system based on CT assessment. A sinus group was graded into three: normal or no abnormality = 0, partial opacification = 1 and total opacification =2. Endoscopic scoring was also developed: No polyp seen = 0, polyp confined to the middle meatus= 1, and polyp beyond the middle meatus =2.

Bhattacharyya et al.[28] evaluated the Lund scoring system and found to have above-average specificity and a reliable sensitivity for the diagnosis of chronic sinusitis with sinonasal polyp.

Treatment is usually medical or surgical. Medical therapy includes the use of antibiotics, antihistamines, steroids and immunotherapy[29]. Patients with sinonasal polyp and chronic sinusitis are commonly refractory to medical therapy[30]. The option of surgery is usually indicated when medical therapy has not been successful. The surgical options include FESS and Caldwell-Luc[31]. The index patient received both medical and surgical therapy.

Histologically, nasal polyps can be divided into four[32]:

- Edematous, eosinophilic nasal polyp: accounts for 85-90% of nasal polyps and is usually bilateral.
- Chronic inflammatory polyp: accounts for only about 10% of nasal polyps.
- Polyps with hyperplasia of seromucinous glands: accounts for only about 5% of the sinonasal polyps.

➤ Polyps with atypical stroma: accounts for less than 1%.

Chronic sinusitis and sinonasal polyp have similar histology. Different authors, however, have varying opinions about this. Some authors documented eosinophilia in chronic sinusitis,[33][34] lymphocytes and plasma cells[35] while another found more neutrophils than eosinophils, basophils and mast cells in patients with chronic sinusitis[25]. Malekzadeh et al.[36] proposed two histological subtypes of chronic rhinosinusitis viz: eosinophilia and polyposis formation being the first type while glandular hyperplasia and hypertrophy is the second type. Edematous eosinophilic cells were seen following the histology of the index case.

#### IV. CONCLUSION

Chronic sinusitis with sinonasal polyp is a chronic disease that affects the patient's quality of life if not promptly diagnosed and treated. Radiologists should have a high index of suspicion especially if there is a history of failed medical therapy and when endoscopy could not be done.

#### ACKNOWLEDGMENT

I acknowledge the contributions of Dr Mbam TT, Dr Ekeh (Department of Otorhinolaryngology, Alex-Ekwueme Federal Teaching Hospital Abakaliki) and Dr Chinwike CC ( Department of Radiology, Alex-Ekwueme Federal Teaching Hospital Abakaliki)

#### REFERENCES

- [1]. Fokkens WJ, Lund VJ, Mullol J, Bachert C, Alobid I, Baroody F, et al. European position paper on rhinosinusitis and nasal polyps 2012. *Rhinol Suppl* 2012;23:1-298.
- [2]. Larsen PL, Tos M. Origin of nasal polyps. *Laryngoscope* 1991; 101(3):305-312.
- [3]. Hopkins C, Browne JP, Slack R, Lund V, Topham J, Reeves B, et al. The national comparative audit of surgery for nasal polyposis and chronic rhinosinusitis. *Clin Otolaryngol* 2006;31:390-398.
- [4]. Kim YS, Kim NH, Seong SY, Kim KR, Lee GB, Kim KS. Prevalence and risk factors of chronic rhinosinusitis in Korea. *Am J Rhinol Allergy* 2011;25:117-121.
- [5]. Ian S.Mackay. Anatomy of the nose. In: Settipane GA, editor. *Nasal polyps: epidemiology, pathogenesis and treatment*. Providence, Rhode Island: OceanSide Publications, Inc., 1997.
- [6]. Mainz JG, Koitschev A. Pathogenesis and management of nasal polyposis in cystic fibrosis. *Curr Allergy Asthma Rep.* 2012;12(2):163-174.
- [7]. Settipane GA. Epidemiology of nasal polyps. *Allergy Asthma Proc* 1996;17:231-236.
- [8]. Aukema AA, Mulder PG, Fokkens WJ. Treatment of nasal polyposis and chronic rhinosinusitis with fluticasone propionate nasal drops reduces the need for sinus surgery. *J Allergy Clin Immunol* 2005;115:1017-1023.
- [9]. Simon HU, Yousefi S, Schranz C, Schapowal A, Bachert C, Blaser K. Direct demonstration of delayed eosinophil apoptosis as a mechanism causing tissue eosinophilia. *J Immunol* 1997;158:3902-3908.
- [10]. Brain DJ. Historical background. In: Settipane G.A., editor. *Nasal polyps: epidemiology, pathogenesis and treatment*. Providence, Rhode Island: OceanSide Publications, Inc., 1997.
- [11]. Kale SU, Mohite U, Rowlands D, Drake-Lee AB. Clinical and histopathological correlation of nasal polyps: are there any surprises? *Clin Otolaryngol* 2001; 26(4):321-323.
- [12]. Settipane GA, Chafee FH. Nasal polyps in asthma and rhinitis. A review of 6,037 patients. *J Allergy Clin Immunol* 1977; 59(1):17-21.
- [13]. In: Settipane GA, editor. *Rhinitis*. OceanSide Publications, Providence, 1992: 175-176
- [14]. Hedman J, Kaprio J, Poussa T, Nieminen MM. Prevalence of asthma, aspirin intolerance, nasal polyposis and chronic obstructive pulmonary disease in a population-based study. *Int J Epidemiol* 1999; 28(4):717-722.
- [15]. Johansson L, Akerlund A, Holmberg K, Melen I, Bende M. Prevalence of nasal polyps in adults: the Skovde population-based study. *Ann Otol Rhinol Laryngol* 2003; 112(7):625-629.
- [16]. Drake-Lee AB, Lowe D, Swanston A, Grace A. Clinical profile and recurrence of nasal polyps. *J Laryngol Otol* 1984; 98(8):783-793.
- [17]. Triglia JM, Nicollas R. Nasal and sinus polyposis in children. *Laryngoscope* 1997; 107(7):963-966.
- [18]. Min YG, Jung HW, Kim HS, Park SK, Yoo KY. Prevalence and risk factors of chronic sinusitis in Korea: results of a nationwide survey. *Eur Arch Otorhinolaryngol* 1996; 253(7):435-439.
- [19]. Lanza DC, Kennedy DW. Adult rhinosinusitis defined. *Otolaryngol Head Neck Surg* 1997; 117(3 Pt 2):S1-S7.
- [20]. Adams PF, Schoenborn CA, Moss AJ, Warren CW, Kann L. Health-risk behaviors among our nation's youth: United States, 1992. *Vital Health Stat* 10 1995;(192):1-51.
- [21]. Kaliner MA, Osguthorpe JD, Fireman P, Anon J, Georgitis J, Davis ML. Sinusitis: bench to bedside. Current findings, future directions. *J Allergy Clin Immunol* 1997; 99(6 Pt 3):S829-S848.
- [22]. Gwaltney JM, Jr. Acute community-acquired sinusitis. *Clin Infect Dis* 1996; 23(6):1209-1223.
- [23]. Gordts F, Clement PA, Destryker A, Desprechins B, Kaufman L. Prevalence of sinusitis signs on MRI in a non-ENT paediatric population. *Rhinology* 1997; 35(4):154-157.

- 
- [24]. Larsen K, Tos M. The estimated incidence of symptomatic nasal polyps. *Acta Otolaryngol* 2002; 122(2):179-182.
- [25]. Bachert C, Cauwenberge P.v. Nasal polyps and sinusitis. In: Adkinson NF, Yunginger JW, Busse WW, Bochner BS, Holgate ST, Simons FR, editors. *Middleton's allergy principles & practice*. St. Louis : Mosby 2003: 1421-1436.
- [26]. Hwang PH, Irwin SB, Griest SE, Caro JE, Nesbit GM. Radiologic correlates of symptom-based diagnostic criteria for chronic rhinosinusitis. *Otolaryngol Head Neck Surg* 2003; 128(4):489-496.
- [27]. Lund VJ, Kennedy DW. Quantification for staging sinusitis. The Staging and Therapy Group. *Ann Otol Rhinol Laryngol Suppl* 1995; 167:17-21.
- [28]. Bhattacharyya N, Fried MP. The accuracy of computed tomography in the diagnosis of chronic rhinosinusitis. *Laryngoscope* 2003; 113(1):125-129.
- [29]. Benninger MS, Anon J, Mabry RL. The medical management of rhinosinusitis. *Otolaryngol Head Neck Surg* 1997; 117(3 Pt2):S41-S49.
- [30]. Hamilos DS. Chronic sinusitis. *J Allergy Clin Immunol* 2000; 106(2):213-227.
- [31]. Bachert C, Hormann K, Mosges R, Rasp G, Riechelmann H, Muller R et al. An update on the diagnosis and treatment of sinusitis and nasal polyposis. *Allergy* 2003; 58(3):176-191.
- [32]. Hellquist H.B. Histopathology. In: Settupane G.A., editor. *Nasal polyps: epidemiology, pathogenesis and treatment*. Providence, R. I.: OceanSide Publications, Inc.: 1997: 41-48.
- [33]. Bryson JM, Tasca RA, Rowe-Jones JM. Local and systemic eosinophilia in patients undergoing endoscopic sinus surgery for chronic rhinosinusitis with and without polyposis. *Clin Otolaryngol* 2003; 28(1):55-58.
- [34]. Sobol SE, Fukakusa M, Christodouloupoulos P, Manoukian JJ, Schloss MD, Frenkiel S et al. Inflammation and remodeling of the sinus mucosa in children and adults with chronic sinusitis. *Laryngoscope* 2003; 113(3):410-414.
- [35]. Stierna P, Carlsoo B. Histopathological observations in chronic maxillary sinusitis. *Acta Otolaryngol* 1990; 110(5-6): 450-458
- [36]. Malekzadeh S, McGuire JF. The new histologic classification of chronic rhinosinusitis. *Curr Allergy Asthma Rep* 2003; 3(3):221-226.