

# Ridge Split Technique Using Piezosurgery - A Case Report

Dr.Missriya  
Postgraduate student  
Department of Periodontology  
AJIDS

Dr.Parimala Kumar  
Reader  
Department of Periodontology  
AJIDS

Dr.Shantala Kalagujji  
Postgraduate student  
Department of Periodontology  
AJIDS

## Abstract:

### ➤ Aim:

**To augment the residual alveolar ridge using ridge augmentation procedure prior to implant placement.**

### ➤ Materials and Methods:

**In the present case, Ridge Augmentation procedure was carried out via the piezoelectric assisted ridge split technique**

### ➤ Results:

**The surgical site healing was uneventful, along with a successful gain in the clinical ridge width post-operatively**

### ➤ Conclusion:

**The staged approach to implant reconstruction by ridge split technique has shown to have better buccal cortical bone preservation, higher implant success and also provide more predictable and stable results.**

The various pre-implant bone augmentation surgical techniques which assist a dental surgeon in reconstructing deficient alveolar ridge include:

- Guided Bone Regeneration (GBR) with a cancellous graft, onlay/veneer block graft, inlay grafting.<sup>(6,7)</sup>
- Ridge split technique<sup>(8,9)</sup>
- Vertical and horizontal distraction osteogenesis.<sup>(2)</sup>

Although ridge-widening techniques were used in the pre-implant era as a form of pre-prosthetic ridge plasty, there has been renewed interest in such techniques in the past 30 years since the advent of osseointegration and root-form dental implants.

The piezoelectric system is based on the fact that certain crystalline structures such as quartz will be subject to a change in shape when placed within an alternating voltage at an ultrasonic frequency, the resultant vibration produces tip movement that is primarily linear in direction. The advantage of this technique is the ability to cut the hard tissue with simplicity and precision while, avoiding any soft tissue injury.

In 2000, Vercellotti *et al.* renewed this approach for nerve and soft tissue protecting surgery which overcame the limitations of traditional instruments in oral bone surgery. It was first reported for preprosthetic surgery, alveolar crest expansion and sinus grafting.<sup>(10,11)</sup>

In this case report, we present one such clinical scenario where ridge augmentation using a sophisticated surgical technique of piezosurgery.

## I. INTRODUCTION

The use of dental implants for the treatment of edentulism continues to increase worldwide and over the years has evolved into a predictable procedure, which is rapidly becoming the preferred method of tooth replacement.

However, tooth extraction and/or trauma can cause alveolar bone loss that can lead to inadequate horizontal width or vertical height, which may hamper the placement of a dental implant.

The treatment modalities for clinical scenarios as these include 2-dimensional (2D) and 3-dimensional (3D) hard-tissue augmentation techniques.

2-dimensional (2D) are mainly designed for vertically preserved but width-deficient alveolar ridges while, 3-dimensional (3D) hard-tissue grafting procedures are intended to gain height and width in volumetrically deficient ridges<sup>(1)</sup>.

## II. CASE REPORT

A 24 year old female patient walked into our OPD with the chief complaint of missing tooth in the upper right, lower left and right back tooth regions since one year. She gave no relevant medical history.

On intraoral examination, partially edentulous teeth were noticed in 14,44 regions and a root-stump was seen in 36.

A diagnosis of Kennedy's Class I in the maxilla and Kennedy's Class I mod 1 in the mandible was given. A treatment plan of implant placement following extraction of 36 was made.

At the 1<sup>st</sup> appointment, complete supragingival and subgingival scaling was performed and oral hygiene instructions were given to the patient.

Following which, routine blood investigations were carried out and an OPG was taken (Fig 1).The radiographic investigation of the desired area revealed a root-stump irt 36 & the distance between the alveolar crest and mandibular canal was found to be 13mm (Fig 2)

The patient was then referred to the Dept. of Oral and Maxillofacial Surgery for the extraction of 36.

In the 2<sup>nd</sup> appointment, clinical examination indicated satisfactory healing irt 36. However, residual ridge width was found to be 3mm (Fig 4) and according to the classification of alveolar ridge width by Tolstunov<sup>(3)</sup> the current case presented a Class IV situation of severe alveolar deficiency.

Class	Alveolar ridge width in mm based on CBCT scan	Alveolar ridge deficiency	Indications for Surgery	Immediate Implant Insertion
0	>10	No deficiency	Hard tissue surgery is not indicated. Occasionally, alveolar width (buccal convexity) can be improved for esthetic reasons with a soft tissue graft	Yes
I	8-10	Minimal	Hard tissue surgery is rarely indicated. Occasionally, alveolar width can be improved by particulate bone graft or palatal soft tissue graft for esthetic and prosthetic reasons	Yes
II	6-8	Mild	Particulate (GBR) grafting or ridge - split is often needed to improve labial bone projection and proper occlusal implant position	Yes/no, depends on presence of apical bone for primary implant stability
III	4-6	Moderate	An ideal width for the ridge-split procedure that can be done in a single- or two-stage approach [Figure 3]. Block graft or GBR can also be done	Yes/no, depends on presence of apical bone for primary implant stability
IV	2-4	Severe	Ridge-split or block bone graft is a graft of choice (surgeon's experience)	Not recommended
V	<2	Extreme	Large extraoral block graft is a preferable surgical choice. Alternative is multiple and sequential augmentation procedures	No
VI	6-10/2-4	"Hourglass" (undercut) (buccal or lingual)	GBR at the mid ridge level can be done	Yes/no, depends on the severity of the undercut
VII	2-4/6-10	"Bottleneck"	Ridge reshaping or GBR at the top of the ridge can be done	Usually yes, can depend on the morphology of the top portion of the ridge

CBCT=Cone beam computed tomography, GBR=Guided bone regeneration

Table 1:- Tolstunov's classification of alveolar ridge width

Hence, an Alveolar Ridge Split technique was planned to achieve hard tissue augmentation prior to implant placement.

Patient was prepped for the surgery that included presurgical chlorhexidine mouthrinse, painting povidoneiodine around the surgical site and administration of local anesthesia.

Firstly, midcrestal and crevicular incisions were given using the no.15 surgical blade (Fig 5,6). Following which, flap was reflected irt 36 (Fig 7) and the underlying bone was exposed. The horizontal ridge width was visualized and examined using William's periodontal probe to be 4mm (Fig 8)

In this case, ridge-split was performed using Piezosurgical unit.

The use of piezosurgical inserts provides multiple perks such as<sup>(4,5)</sup>:

- Microprecision
- Selective cutting of hard tissue
- Maximum visibility
- Excellent healing

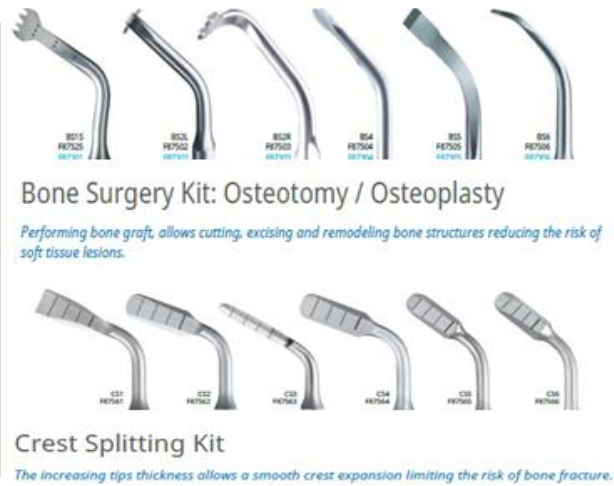

Table 2

The BS2 piezo insert tip was used to achieve the initial ridge split(Fig9) and subsequently chisel and mallet was used to expand the ridge further(Fig10). The desired split depth of 8mm was achieved (Fig11,12), after which the distance between the two split halves amounted to 9mm (Fig13,14).

The space between the split halves was grafted using xenograft (Fig15). Healiguide collagen membrane was then placed over the ridge(Fig16) and sutures were given (Fig17).

The patient was evaluated 2 weeks post-operatively; the surgical site presented satisfactory healing with no associated complications (Fig18).

The patient was re-evaluated 45 days post-operatively; during which clinically ridge width of 10mm was an Intraoral Periapical Radiograph(IOPA) was taken irt 36 revealed adequate bone fill.

The piezoelectric assisted alveolar ridge split technique was used successfully to gain a clinical ridge width of 10mm (Fig19) and pre- and post-procedural radiographic examination displayed adequate bone fill 45 days post-operatively (Fig20,21).

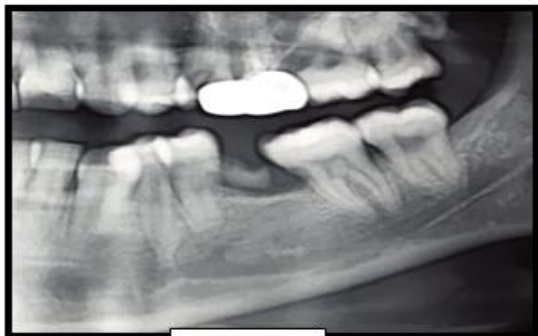

FIG 1

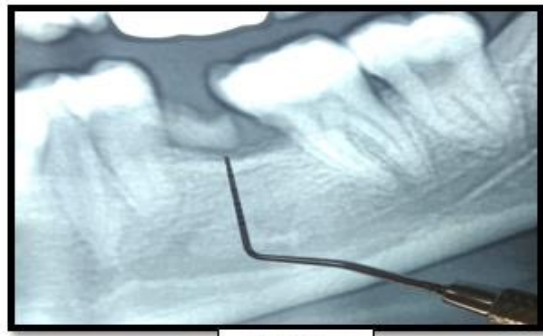

FIG 2

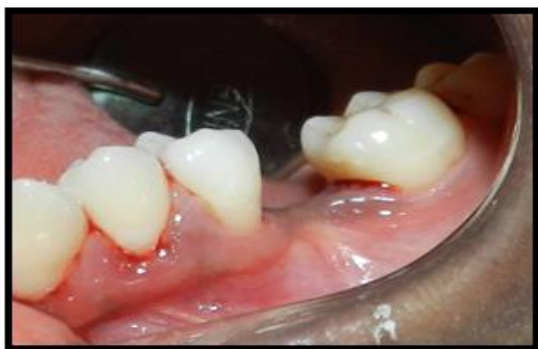

FIG 3

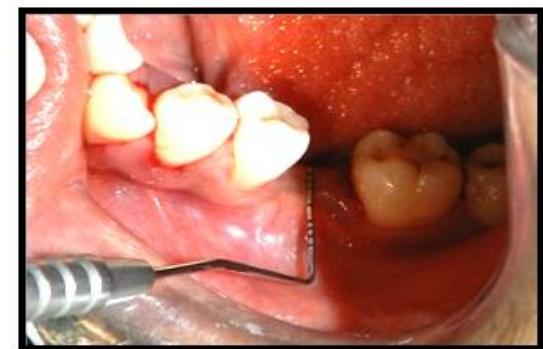

FIG 4

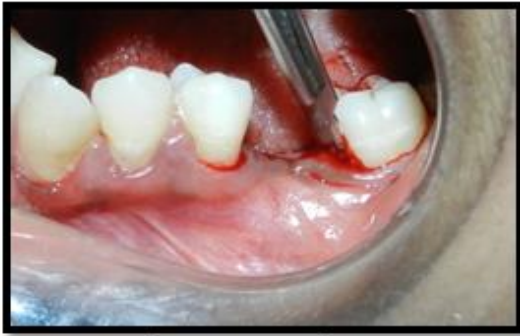

FIG 5

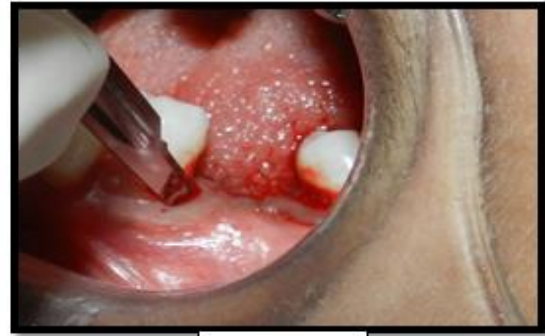

FIG 6

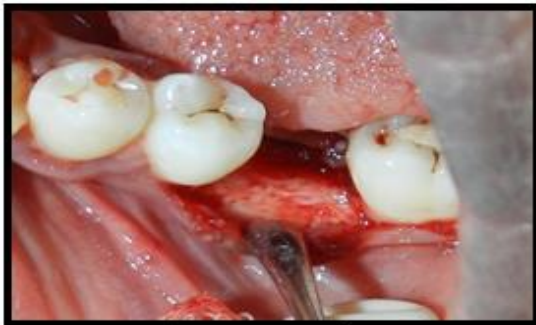

FIG 7

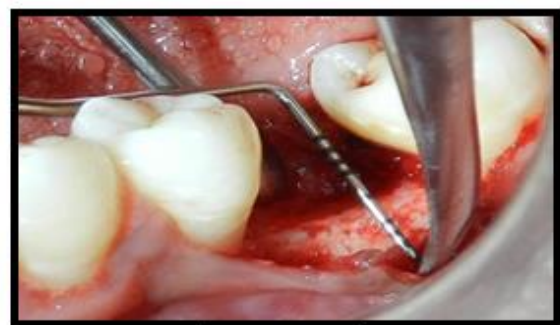

FIG 8

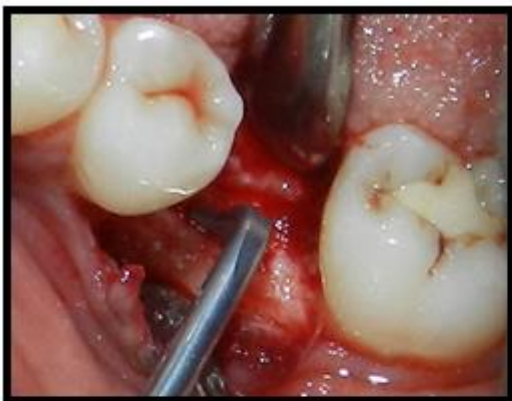

FIG 9

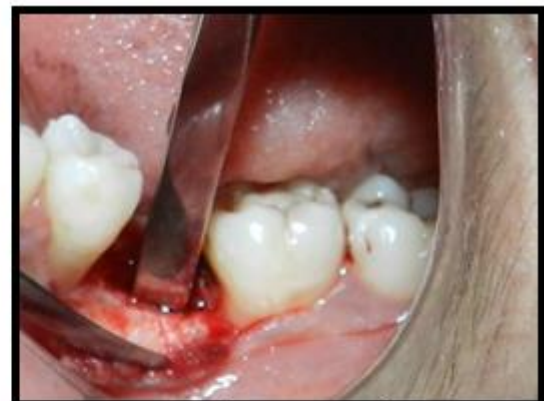

FIG 10

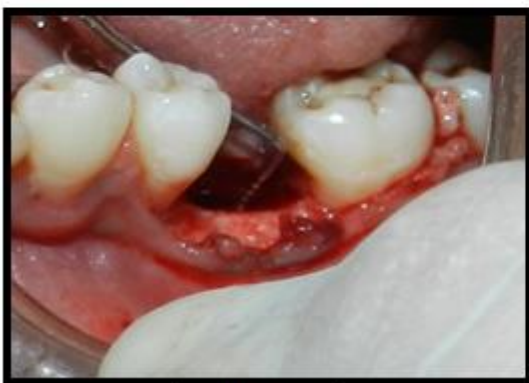

FIG 11

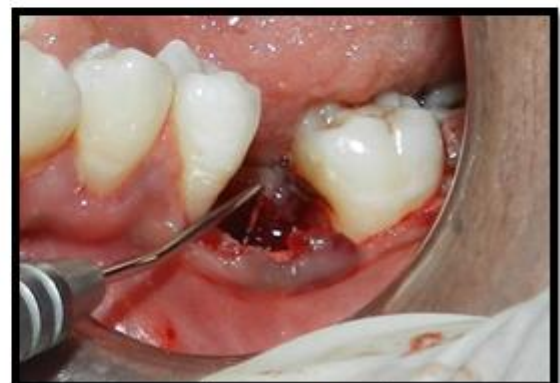

FIG 12

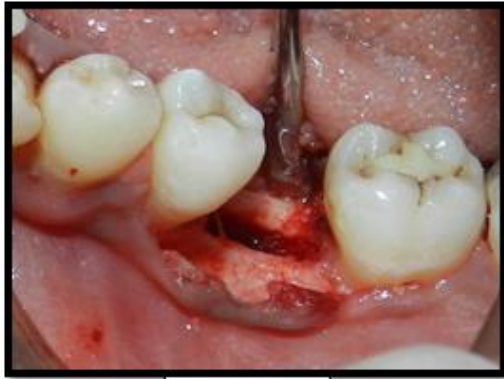

FIG 13

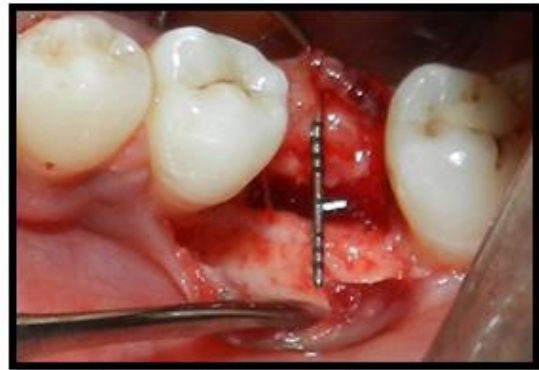

FIG 14

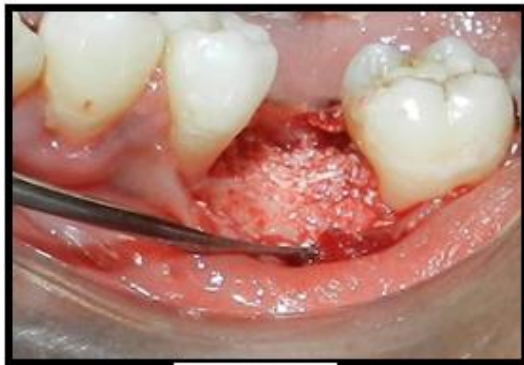

FIG 15

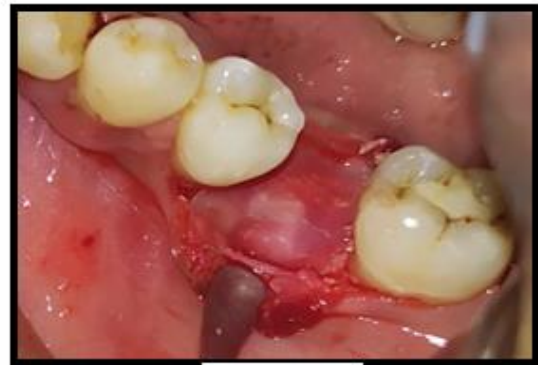

FIG 16

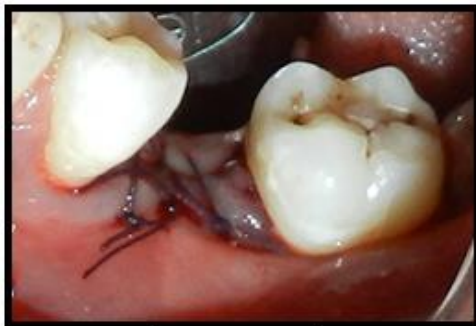

FIG 17

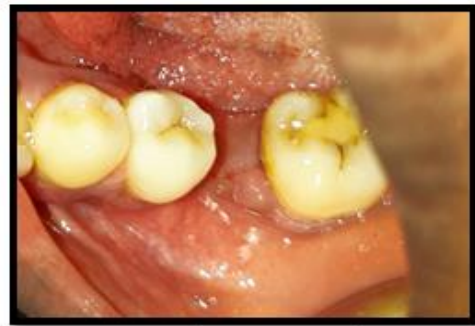

FIG 18

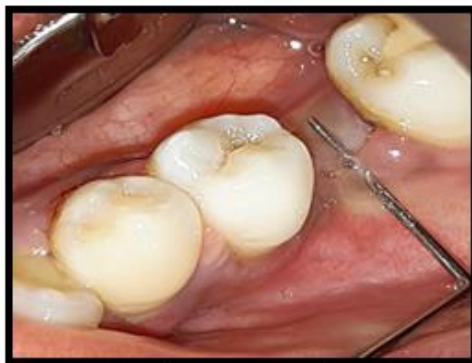

FIG 19

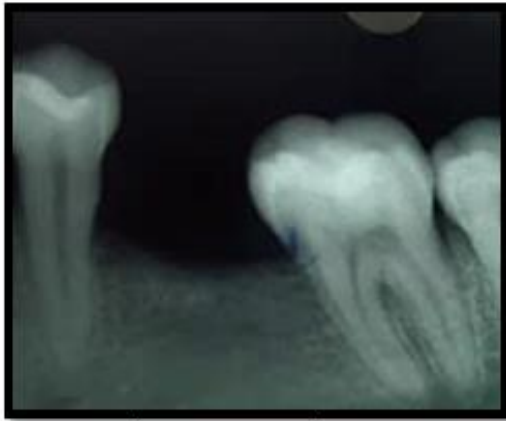


FIG 20

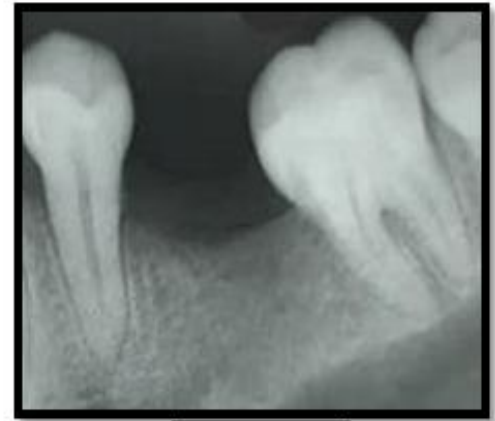

FIG 21

### III. DISCUSSION

Ridge expansion discloses certain technical and physiological limitations. One major drawback of alveolar bone splitting is the requirement of a cancellous bone compartment between the buccal and lingual plates to allow separation.

Consequently, although in many cases mainly the mandible is affected by horizontal bone resorption the lack of enough extendable trabecular bone volume often confines the technique to the maxilla. Moreover, without any further modification of the surgical technique or integration of additional grafting techniques collateral missing vertical bone height cannot be sufficiently rebuilt.

Another disadvantage of the alveolar bone splitting technique, which can be quite severe, may be the risk for bone resorption due to malnutrition of the laterally out displaced buccal bone wall. Although, some approaches were proposed to reduce bone resorption evidence for their efficacy is still lacking.

### IV. CONCLUSION

The literature has demonstrated the predictability of the Ridge Split technique in cases of narrow alveolar ridges that can be widened in preparation for an implant placement.

Also, the staged approach to implant reconstruction by ridge splitting tends to have better buccal cortical bone preservation, higher implant success. <sup>(2)</sup>

### REFERENCES

- [1]. Chatterji A, Show S, Kundu R et.al. "Un-Orthodox"...a new paradigm in ortho-implant intervention. *International Journal of Science & Healthcare Research*. 2020; 5(1): 12-18.
- [2]. Elian N, Jalbout Z, Ehrlich B, et al. A two-stage full-arch ridge expansion technique: review of the literature and clinical guidelines. *Implant Dent*. 2008;17:16–23.
- [3]. Tolstunovs classification of alveolar ridge width; *Indian journal of dental research* 2017.
- [4]. Jaishree T et al. Piezosurgery: Ultrasonic bone surgery in periodontics and oral implantology – Review. *Int.Jou*.
- [5]. Deepa D, Jain G, Bansal T. Piezosurgery in dentistry. *J Oral Res Rev* 2016;8:27-31
- [6]. Misch CE. Maxillary sinus augmentation for endosteal implants. Organized alternative treatment plans. *Int J Oral Implantol*. 1987;4:554-558.
- [7]. Sindet Pederson S, Enemark H. Reconstruction of alveolar clefts with mandibular or iliac bone grafts. *Int J Oral Maxillofac Surg*. 1990;2:91-96.
- [8]. Duncan JM, Westwood M. Ridge widening for the thin maxilla: A clinical report. *Int J Oral Maxillofac Implants*. 1997; 12:224-227.
- [9]. Summers R. The ridge expansion osteotomy. *Compend Contin Educ Dent*. 1992;12:463-466.
- [10]. Bains VK, Mohan R, Bains R. Application of ultrasound in periodontics: Part II. *J Indian Soc Periodontol* 2008;12:55-61.
- [11]. Stübinger S, Kuttnerberger J, Filippi A, Sader R, Zeilhofer HF. Intraoral piezosurgery: Preliminary results of a new technique. *J Oral Maxillofac Surg* 2005;63:1283-7.