

# Knowledge about Gummy Smile and its Treatment Options among Dental Students

<sup>1</sup>Dr. Uma Sudhakar, Head and Professor, Thai Mookambigai Dental College and Hospital, Chennai, Tamilnadu.

<sup>2</sup>Dr. Snophia Suresh, Professor, Thai Mookambigai Dental College and Hospital, Chennai, Tamilnadu.

<sup>3</sup>N.Sri Hamsika, Student - Intern, Thai Mookambigai Dental College and Hospital, Chennai, Tamilnadu.

<sup>4</sup>D.Shalini, Student- Intern, Thai Mookambigai Dental College and Hospital, Chennai, Tamilnadu.

<sup>5</sup>B.Srinidhi, Student -Intern, Thai Mookambigai Dental College and Hospital, Chennai, Tamilnadu.

## Abstract:-

### ➤ Aim:

The purpose of this study /survey was to determine the knowledge about gummy smile and its treatment options among dental students.

### ➤ Background:

A harmonic smile should show the whole extension of incisors, canines and pre molars and has a slight touch of those teeth on the lower and upper lip curvature. Excessive gingival display may make the smile displeasing or even repulsive. Nowadays, gummy smile correction is becoming a prime treatment objective in response to patient demand. The gummy smile is diagnosed when there is 3 mm or more gingival tissue in smile. The etiologies that play role in the gummy smile are often multifactorial, like extrusion of the upper-anterior teeth, upper alveolar protrusion, short clinical crown, short lip, altered passive eruption and vertical maxillary excess. Treatment options are surgical, orthodontics, Botox lasers and various other options are available.

### ➤ Methods:

A link of a questionnaire comprising 25 questions were sent among 110 students. Students who participated in survey were asked about a gummy smile, causes of gummy smile, normal lip length, forms of periodontium, botox its mechanism, methods of injecting Botox, side effects about surgical treatment and orthodontic treatment. Data was collected through google forms.

### ➤ Results:

The study results suggests a synergistic relationship between various treatment modalities of gummy smile. The decision of the treatment method lies purely in the hands of a clinician. Patients expectation, expenditure, and esthetic sense also play a vital role. This survey presents that the participants have good knowledge about the factors associated with gummy smile. 84.5% of people were aware that short clinical crowns may be a cause of gummy smile in patients whose gingiva is absolutely normal. 71.8% of people also correctly answered that high smile line was seen in gummy smile patients. Improvisation is needed in the

field of BOTOX for treating gummy smile as it can be the most promising method in the near future.

### ➤ Conclusions:

In a nutshell we arrived to the point that dental students who are majorly undergraduates have fair knowledge about gummy smile, and its etiology, but they lacked knowledge on diagnosing factors such as length of upper lip, its length as age advances, basic forms of periodontium that needs to be assessed for gummy smile.

**Keywords:** Gummy smile, Esthetics, Botox, Lip length.

## I. INTRODUCTION

People's concern about beauty and attractiveness increases day by day. Smile is the beauty criteria in society today[1]. Smile is a killer tool for some people but can be problem for some people. Excessive gingival display "gummy smile" has negative effect on esthetics. It occurs more in females than males[2]. Several etiologic factors include skeletal, inguinal, muscular (or) combination of these [3]. Other reasons are delayed teeth eruption, excessive teeth coverage by gingiva, skeletal problem related to the maxilla and inadequate lip movement. Gummy smile due to skeletal or dental defects are better treated orthodontically. Smile starts with contraction of perioral muscles [4]. Soft tissue defects associated with gummy smile are short upper lip, hyper functioning of muscles, gingival enlargement. Modern methods like LASER, BOTOX injections are available. Lips are the framework of the dental elements. Degree of exposure of dentogingival unit depends on size, shape and fullness of the lips. Lip repositioning surgery is the viable option. Rubinstein and Kostianovsky described this procedure first in their literature [5]. Amount of mucosa removed is twice the amount of gingival display [6]. LASER and electrocautery are new venture for this procedure. BOTOX(Botulinum toxin) is produced by C.botulinium. Eight stereotypes are available of which BTX-A is commonly used [7]. It blocks neuromuscular transmission but effects may be transient. Botox is approved by the Food and Drug Administration to be effective for treating strabismus, hemi-facial spasms and glabellar lines [8]. It is the best practicable non-surgical procedure in this era. A good diagnosis is needed for a right

treatment plan [9]. With the modern technique in this contemporary world, a balanced smile created.

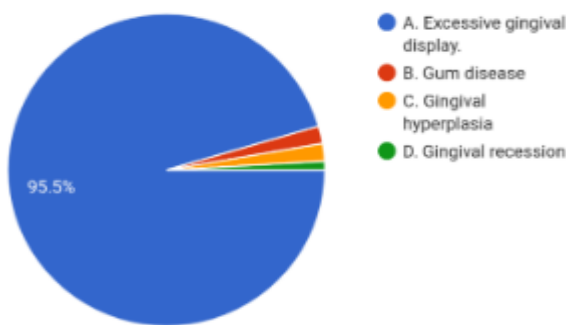
**II. MATERIALS AND METHODOLOGY**

Survey questions were distributed as google forms to dental students. A total of 110 questionnaire forms were sent. 20 questions were framed up with choice of four options respective to each question was made. The framework covered knowledge of dental students about a gummy smile and just its respective treatment options. Questions were framed containing multiple choices and students were asked to opt for a single answer. The survey was conducted among third year, final year and internship students of Thai Moogambigai Dental College Hospital, Chennai, India. The questions were about gummy smile diagnosis, etiology and treatment plan. Ethical committee approval was acquired from the university. The students were verified about the survey and informed consent was obtained.

**III. RESULTS**

**1. What is gummy smile?**

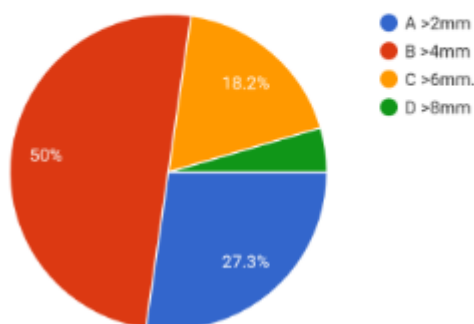
110 responses



Out of 110 students, for Question No. 1: 95.5% of people selected the correct option A- Excessive gingival display. Remaining percentage of people selected other options.

**2. How much exposure of gingiva is considered as gummy smile?**

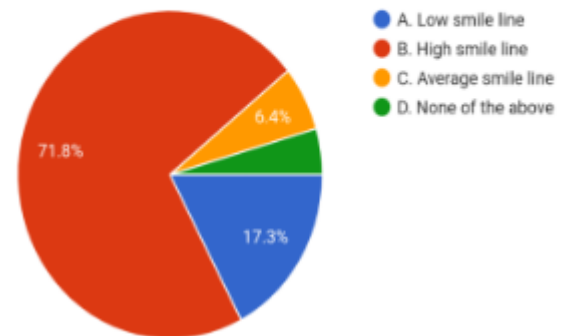
110 responses



Out of 110 students, for Question No. 2: 50% of people selected the correct option B - 4mm. Remaining percentage of people selected other options.

**3. What is the type of smile is seen in gummy smile?**

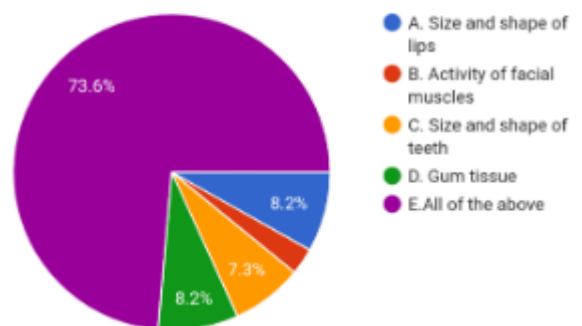
110 responses



Out of 110 students, for Question No. 3: 71.8% of people selected the correct option B- High smile line. Remaining percentage of people selected other options.

**4. What are the factors that causes gummy smile?**

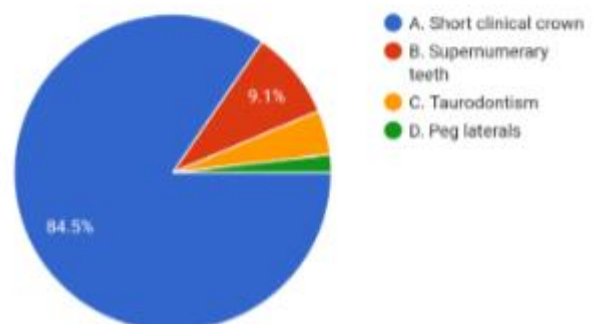
110 responses



Out of 110 students, for Question No. 4: 73.6% of people selected the correct option E-All of the above. Remaining percentage of people selected other options.

**5. Tooth related factors that can cause gummy smile?**

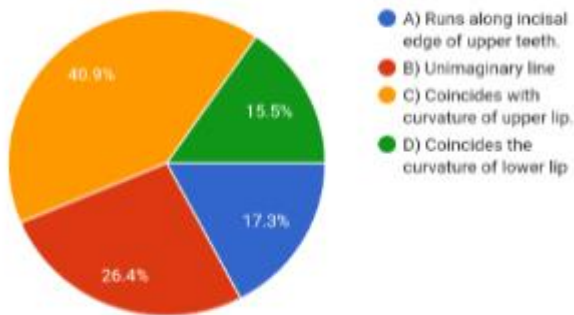
110 responses



Out of 110 students, for Question No. 5: 84.5% of people selected the correct option A-Short clinical crown. Remaining percentage of people selected other options.

6. Which of the following is true about smile line in gummy smile?

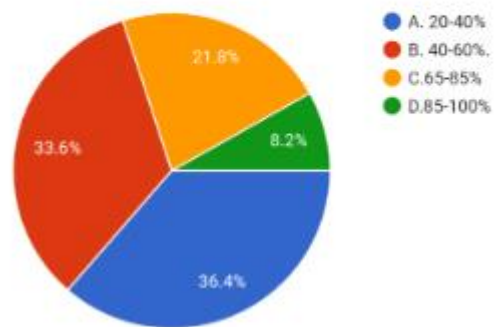
110 responses



Out of 110 students ,for Question No. 6 :40.9% of people selected the correct option C- Coincides with curvature of upper lip. Remaining percentage of people selected other options.

9. What is the gold standard proportion for the exposure of maxillary central incisor?

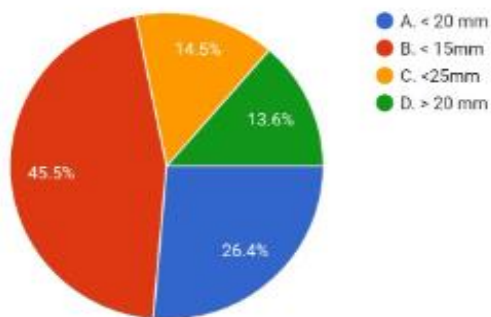
110 responses



Out of 110 students ,for Question No. 9: 21.8% of people selected the correct option C(65-85%) Remaining percentage of people selected other options.

7. At what length of upper lip will the dentogingival complex get displayed?

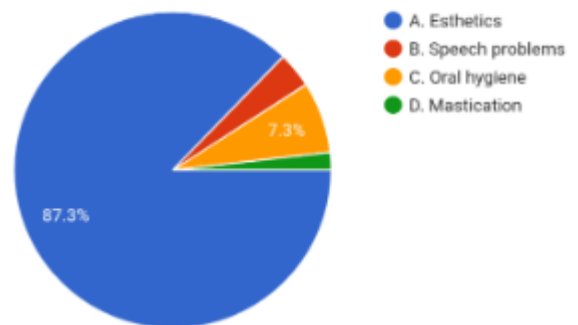
110 responses



Out of 110 students ,for Question No.7:45.5% of people selected the correct option B- (<15mm) Remaining percentage of people selected other options.

10. Why do you think gummy smile needs to be treated?

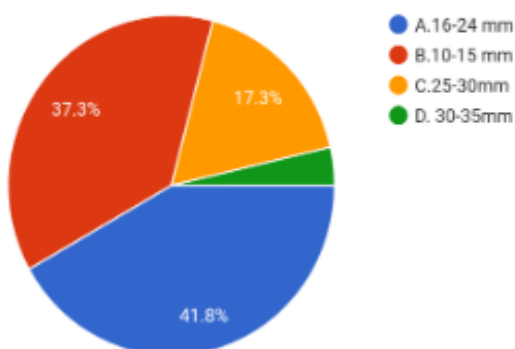
110 responses



Out of 110 students, for Question No. 10: 87.3% of people selected the correct option A -Esthetics. Remaining percentage of people selected the other options.

8. What is the normal length of upper lip?

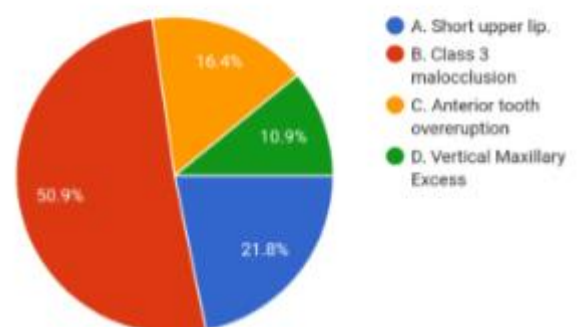
110 responses



Out of 110 students ,for Question No. 8 :41.8% of people selected the correct option A(16-24mm) . Remaining percentage of people selected other options.

11. All of these are causes of gummy smile except?

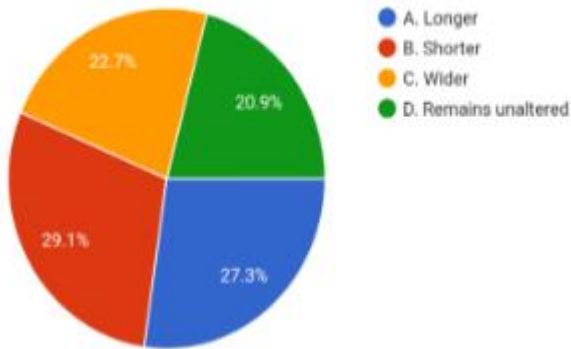
110 responses



Out of 110 students ,for Question No. 11 :50.9% of people selected the correct option B-Class3 malocclusion. Remaining percentage of people selected other options.

12. As age advances lip length becomes ?

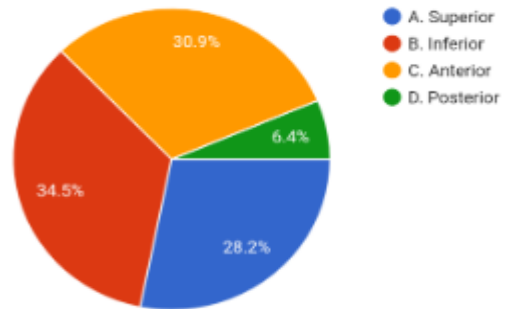
110 responses



Out of 110 students ,for Question No. 12 : 27.3% of people selected the correct option A-Longer. Remaining percentage of people selected other options

15. Overgrowth of maxillary alveolus in which direction causes gummy smile?

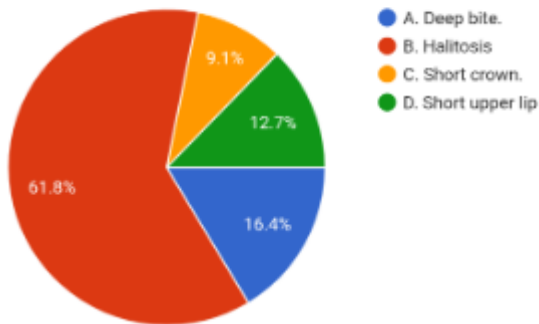
110 responses



Out of 110 students ,for Question No. 15 :34.5% of people selected the correct option B – Inferior. Remaining percentage of people selected other options.

13. All of the following are associated with gummy smile except?

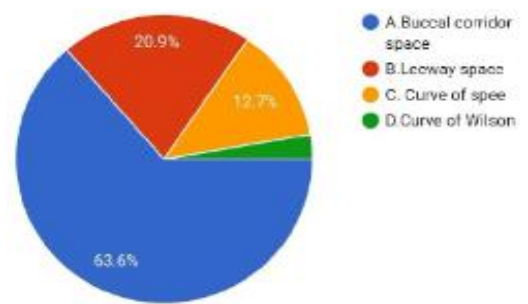
110 responses



Out of 110 students ,for Question No. 13: 61.8% of people selected the correct option B -Halitosis Remaining percentage of people selected other options

16. The negative space between buccal surface of posterior teeth and corner of lips when patient smiles is called as ?

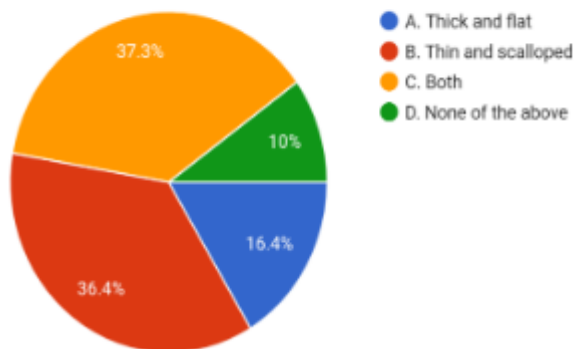
110 responses



Out of 110 students ,for Question No.16 :63.6% of people selected the correct option A- Buccal corridor space.Remaining percentage of people selected other options.

14.Basic forms of periodontium?

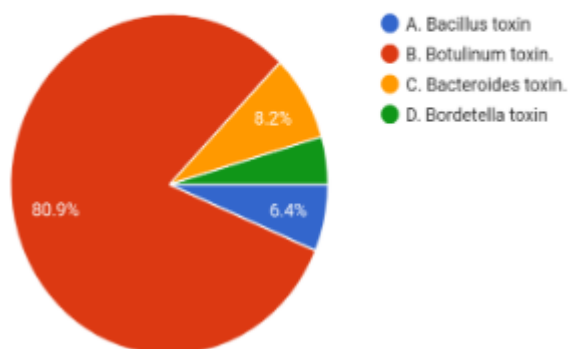
110 responses



Out of 110 students ,for Question No. 14: 37.3% of people selected the correct option C- Both. Remaining percentage of people selected other options

17. What is the full form of Botox?

110 responses

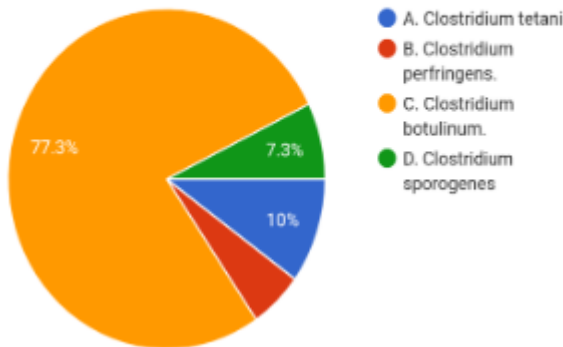


Out of 110 students ,for Question No.17 :80.9% of people selected the correct option B – Botulinum toxin Remaining percentage of people selected other options.



18. Botox is produced by the bacterium?

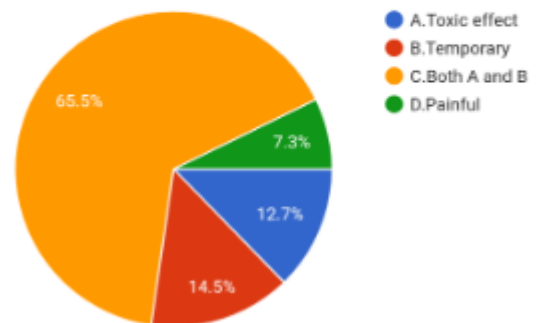
110 responses



Out of 110 students ,for Question No 18 :77.3% of people selected the correct option C-Clostridium botulinum. Remaining percentage of people selected other options.

21. Why botox is usually not preferred among patients?

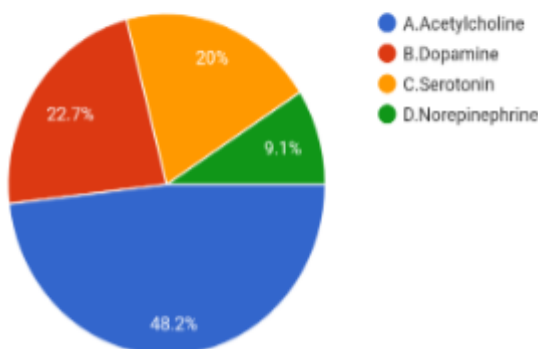
110 responses



Out of 110 students ,for Question No.21 :65.5% of people selected the correct option C- Both A and B. Remaining percentage of people selected other options.

19. Botox prevents release of

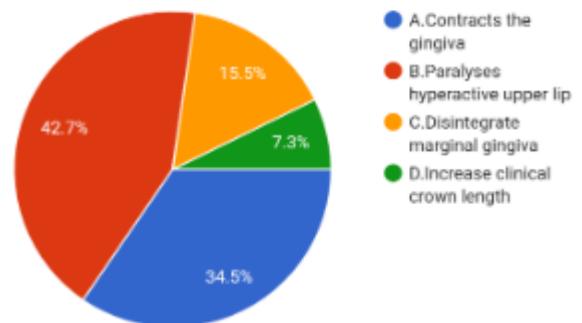
110 responses



Out of 110 students ,for Question No. 19:48.2% of people selected the correct option A- acetylcholine. Remaining percentage of people selected other options.

22. The mechanism of botox in treating gummy smile?

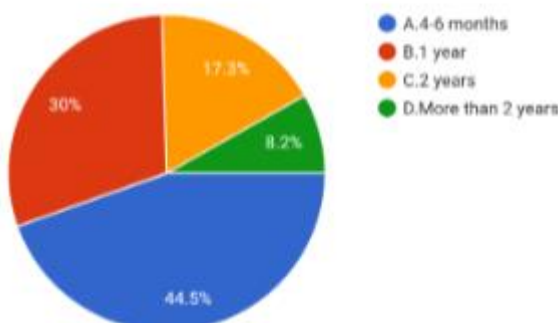
110 responses



Out of 110 students ,for Question no 22, 42.7% of people selected the correct option B- Paralyzes of hyperactive upper lip. Remaining percentage of people selected other options.

20. How long does Botox treatment last for gummy smile?

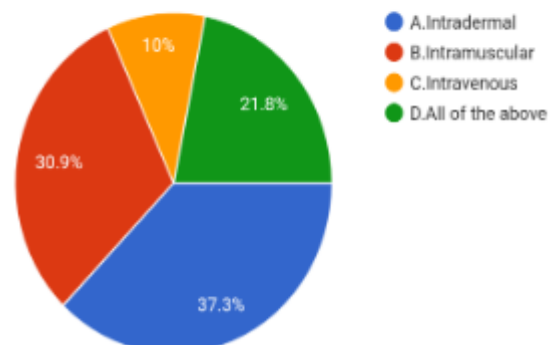
110 responses



Out of 110 students ,for Question no 20. : 44.5% of people selected the correct option A(4-6 months). Remaining percentage of people selected other options.

23. What are the methods of injecting botox?

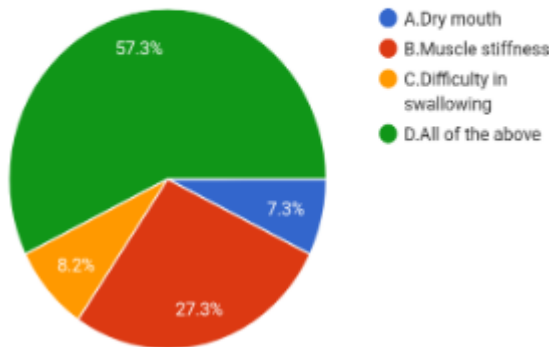
110 responses



Out of 110 students ,for Question No. 23 :30.9% of people selected the correct option B- intramuscular. Remaining percentage of people selected other options.

**24.What are the side effects of botox?**

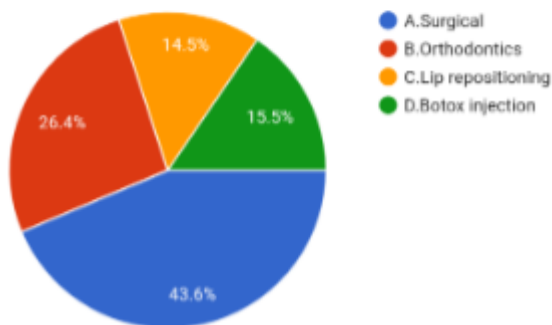
110 responses



Out of 110 students ,for Question No. 24 :57.3% of people selected the correct option D- All of the above. Remaining percentage of people selected other options.

**25.What do you think is the best way to treat this condition?**

110 responses



Out of 110 students ,for Question No. 25 :43.6% of people selected the correct option A- Surgical. Remaining percentage of people selected other options.

**IV. DISCUSSION**

Many surgical techniques for correction of the gummy smile have been advocated to favor the rising demands of aesthetics. Exaggerated display of gingiva associated with short clinical crowns or excessive gingival coverage due to delayed teeth eruption must be ruled out during differential diagnosis in order to arrive at a final diagnosis of a true gummy smile[9]. Certain amount of gingival display while smiling is considered to be acceptable since it adds to aesthetic appearance [10-11] . The clinician must be able to cater the treatment to the patient’s specific needs and must present alternative treatment options in order to achieve the ultimate goal [11].

Smile line is grouped as following according to dental literature:

- normal smile line - inferior rim of upper lip has gums measuring 1-2 mm.
- low smile line - inferior rim of upper lip has covered over 25% crown length of incisors.

- High smile line- inferior rim of upper lip covered over 2mm of free marginal gingiva.

Facial aesthetic parameters have to be calibrated by the dentist to assess a normal versus gummy smile. Gummy smile is absolutely a non-pathological condition causing unaesthetic smile, where more than 3 to 4 mm of gingiva is visible during a smile[12]. Laser assisted lip repositioning surgery is a good alternative owing to it’s simple and less invasive procedure. It requires minimal instrumentation, and promotes excellent postoperative healing. Lasers also have an impact on the activation of gingival fibroblasts to release growth factors [13]. Botox, produced by Clostridium botulinum of anaerobic origin has been used in the treatment of conditions that are associated with excessive muscle contraction. It imparts its action by producing partial chemical denervation thereby reducing the activity of the respective muscle into which it is injected[14].

The present study reveals that the dental students had fairly good knowledge on gummy smile and it’s treatment options. Majority of students who were surveyed had fair knowledge on etiology of gummy smile relating to teeth and periodontal factors. A substantial number of students mentioned that gummy smile treatment is required with regard to esthetic purpose. The awareness about gold standard proportion for exposure of maxillary central incisor was low. The survey revealed students did not have adequate knowledge on methods of injecting botox. The students also have awareness about various treatment options and opted surgical management as the best method in order to overcome the disadvantage of recurrence related to other means of treatment of gummy smile. More interactive sessions could be planned in colleges ,which could improve their knowledge on ways to diagnose a gummy smile.

They lacked knowledge on diagnosing factors such as length of upper lip, its length as age advances, basic forms of periodontium that needs to be assessed for gummy smile. The students seemed to show a good interest in learning and gaining more knowledge about gummy smile etiology, diagnostic methods and treatment options.

**V. CONCLUSION**

This survey indicates that dental undergraduates have fair knowledge about gummy smile. They are aware about the treatment modalities available but lacks definitive knowledge about the diagnostic criteria. Since gummy smile treatment is a multidisciplinary approach sound knowledge on basic dental science is essential. Gummy smile has potential implications on oral health. If left untreated it might have a negative impact on the periodontium. Since some of the treatment options face a drawback of relapse, treatment plan has to be made by all means to avoid it. The dentist must always be updated about treatment methods which may be surgical or non-surgical that has comparatively greater advantage. Adoption of botox as a treatment method necessitates a complete knowledge about its temporary nature, dosage and the area for administering

injection and the probable side effects. The lack of knowledge for a dentist in any one of the stages commencing from etiology to rendering treatment to the patient who is psychologically disturbed because of their compromises esthetics, there occurs failure to meet the expectations of the patient and to create a harmonious smile. This survey appreciates the knowledge of a particular group of students and doesn't indicate everyone.

### REFERENCES

- [1]. Hadeel A Mokhtar, Layla W Abuljadayel, Reem M Al-Ali, Mohammed Yousef .The perception of smile attractiveness among Saudi population.[dx.doi.org/10.2147/CCIDE.S74764](https://doi.org/10.2147/CCIDE.S74764)
- [2]. Levi YLAS, Cota LVS, Maia LP. Digital smile design for gummy smile correction. *Indian J Dent Res* 2019;30:803-6.
- [3]. Ezquerro F, Berrazueta MJ, Ruiz-Capillas A, Arregui JS. New approach to the gummy smile. *Plast Reconstr Surg*. 1999;104:1143–1150.
- [4]. Robbins JW. Differential diagnosis and treatment of excess gingival display. *Pract Periodontics Aesthet Dent*. 1999;11:265–272; quiz 273.
- [5]. Annalisa Monaco, Oriana Streni, Maria Chiara Marci, Giuseppe Marzo, Roberto Gatto, Mario Giannoni. Gummy smile: clinical parameters useful for diagnosis and therapeutical approach. *J Clin Pediatr Dent* 29(1): 19-26, 2004
- [6]. Mario Polo San Juan, Puerto Rico. Botulinum toxin type A in the treatment of excessive gingival display. [doi:10.1016/j.ajodo.2004.09.013](https://doi.org/10.1016/j.ajodo.2004.09.013)
- [7]. Harry Dym, DDS\*, Robert Pierre II, DMD, Diagnosis and Treatment Approaches to a "Gummy Smile" *Dent Clin N Am*
- [8]. Levine RA, McGuire M. The diagnosis and treatment of the gummy smile. *Compend Contin Educ Dent*. 1997;18:757–762, 764; quiz 766.
- [9]. Walid Ahmed Abdullah, Hesham S Khalil, Maryam M Alhindi, Hamdy Marzook- Modifying Gummy Smile: A Minimally Invasive Approach. *The Journal of Contemporary Dental Practice*, November-December 2014;15(6):821-826
- [10]. Peck, S.; Peck, L.; and Kataja, M.: The gingival smile line, *Angle Orthod*. 62:91-100, 1992.
- [11]. Kokich Kokich, V.O.; Kiyak, H.A.; and Shapiro, P.A.: Comparing the perception of dentists and lay people to altered dental esthetics, *J. Esth. Dent*. 11:311-324, 1999.
- [12]. Gibson MP, Tatakis DN. Treatment of Gummy Smile of Multifactorial Etiology: A Case Report. *Clin Adv Periodontics*. 2017 Nov;7(4):167-173.
- [13]. Saygun, I., Karacay, S., Serdar, M., Ural, A.U., Sencimen, M., and Kurtis, B. (2007). Effects of laser irradiation on the release of basic fibroblast growth factor (bFGF), insulin like growth factor-1 (IGF-1), and receptor of IGF- 1(IGFBP3) from gingival fibroblasts. *Lasers Med. Sci*. 23,211–215.
- [14]. Benedetto AV. The cosmetic uses of botulinum toxin type A. *Int J Dermatol* 1999;38:641-55