

Household Orbital Trauma that Nearly Cost Life

El marzouqi Batal 1, Amhoud Karim 2, Belaydi Belaydi 3, Karmoun Souhaila 4, Berraho Amina 5.

Ophthalmology service B, hospital specialties Rabat (CHU Ibn Sina), Mohammed V University, Morocco.

Batal El marzouqi, Ophthalmology service B, hospital specialties Rabat (CHU ibn sina), Mohammed v university, Morocco

Abstract:- This is a clinical case of a child who was the victim of a domestic orbital-cerebral trauma which almost cost him his life, admitted urgently to the operating room after a clinical and radiological check-up and treatment with antibiotics, analgesia and anti-tetanus, it has benefited from an extraction of the foreign body with a good evolution.

Keywords:- Orbital, Trauma, Orbital-Cerebral Scanner, The Base of the Skull.

I. INTRODUCTION

Eye trauma in children is a reason for frequent consultation in ophthalmology, often in a domestic context, and is an important cause unilateral visual disturbance. (2, 3, 5)

II. OBSERVATION

We report the clinical case of a 10 year old patient, with no history, who was victim of a trauma by a screwdriver by her cousin of the same age while playing; the point of orbital impact is below and nasal of the right eye. (Figure1)

The patient was referred from the provincial hospital, the admission examination found a Glasgow coma scale at 15 and all normal constants (TA, T ° ...), visual acuity at 10/10, ocular motility preserved, the rest of the ophthalmological examination is normal, the screwdriver in place at the orbital inferior ocular and nasal level after conditioning brain imaging was performed (standard radiology, cerebral angiography). (Figure 2, 3)

Imaging results: a foreign body passing from the lower and inner edge of the orbit of the right eye reaching almost the base of the skull without vascular lesions in its path, after advice from the neurosurgeons and maxillofacial, tetanus vaccine and intravenous antibiotics, the patient was admitted to the block with maxillofacial, removal of the foreign body under general anesthesia, then constant clinical (monitoring: T°, TA, GCS...), and radiological monitoring (brain scan, 6h after), simple course without complications.

III. CONCLUSION

-Ocular and orbital trauma is common in young children, especially males.

-prevention is mainly based on avoiding sharp objects. (1, 4, 5)

FIGURE

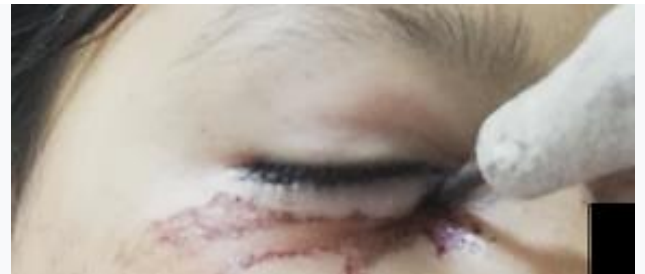

Fig 1:- picture showing the impact point of the Screwdriver

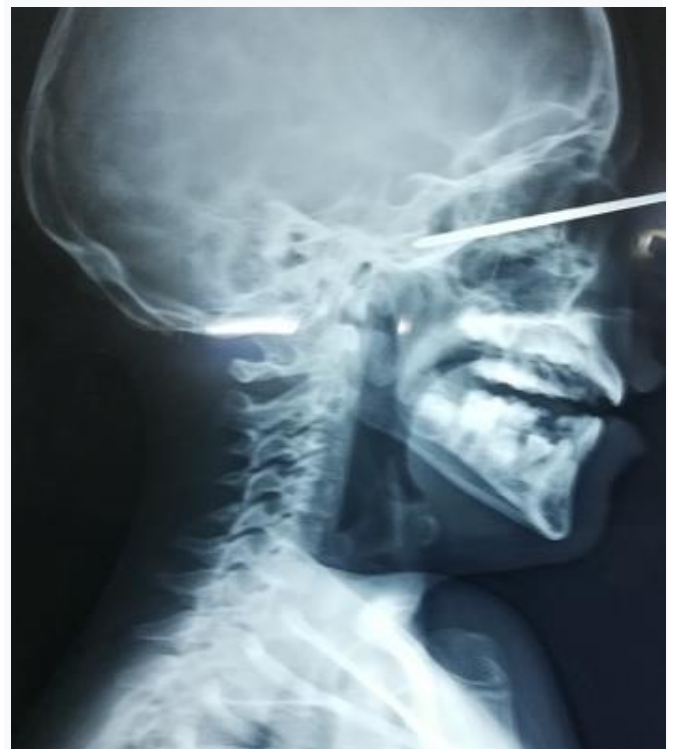

Fig 2:- standard x-ray of the skull, profile view

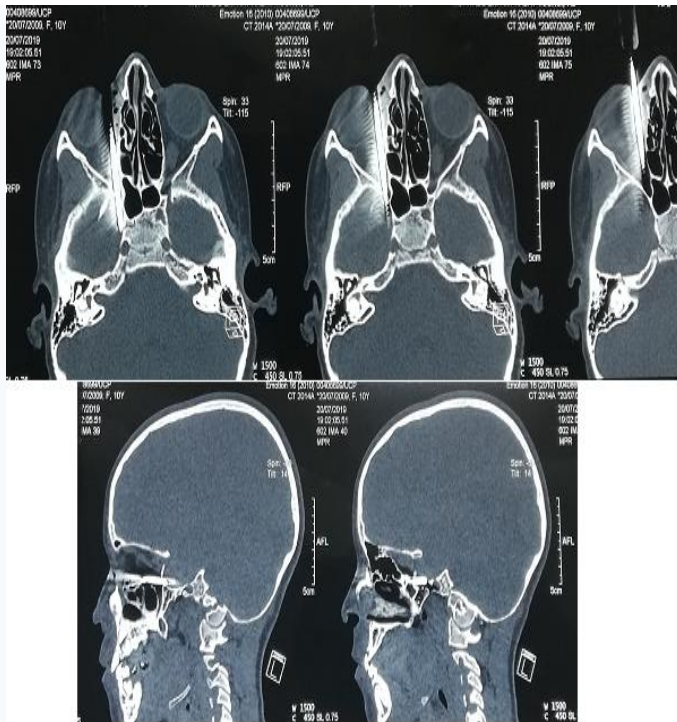


Fig 3:- orbital-cerebral scanner which shows the path of the metallic foreign body

REFERENCES

- [1]. Freihofer Hans Peter M. Effectiveness of secondary post traumatic periorbital reconstruction. *J of Cranio-maxillo-fac Surg*, 1995, 23, 143-150.
- [2]. Meda N, Ouedraogo A, Daboue A, Ouedraogo M, Ramde B, Some D. Etiologies des traumatismes oculo-palpébraux au Burkina Faso. *J Fr Ophtalmol*, 2001, 24, 5, 463-466.
- [3]. Hatton M P, Watkins L M, Rubin P A. Orbital fractures in children. *Ophtalmic Plastic and Reconstructive Surgery*, Vol 17, N°3, p 174-179, 2001.
- [4]. Baggio E. Que faire devant un traumatisme oculaire ou orbitaire de l'enfant ? 14e Journée de l'urgence pédiatrique, janvier 1999.
- [5]. David J. Spalton. Roger A.Hitchings. Paul A .Hunter Traumatologie orbitaire. Atlas d'ophtalmologie clinique troisième édition 2006.