

Meckel Gruber Syndrome: A Case Report

ELBARAKA Yassine¹,
¹Gynecological obstetrics department,
 hospital university Hassan II,
 FEZ.MOROCCO

AMMOR Younes. SAOUD karam, MAMOUNI Nisrine¹,
 ERRARHAY Sanaa¹, BOUCHIKHI Chahrazed¹, BANANI
 Abdelaziz¹
¹Gynecological obstetrics department, hospital university
 Hassan II, FEZ.MOROCCO

Abstract:- Meckel Gruber syndrome is a uncommon poly malformative syndrome. It is an autosomal recessive disorder. The most common malformations found in Meckel syndrome are polycystic renal dysplasia, encephalocele, polydactyly, and hepatic fibrosis. Genetic progress in order to isolate the gene responsible for Meckel syndrome can help diagnosis, especially antenatal diagnosis. We report a case of Meckel syndrome discovered by ultrasound in labor.

Keywords:- Meckel Syndrome, Renal Dysplasia, Polydactyly, Antenatal Diagnosis.

I. INTRODUCTION

The Meckel Gruber Syndrome described by Meckel in 1822, and Gruber in 1934 combining encephalocele, cystic kidney dysplasia, and polydactyly. The variability of the clinical pictures found in the literature shows that the polymorphism of this syndrome is an essential characteristic. Ultrasound is currently the best means of antenatal screening for this lethal poly malformation [1]. We report a case of Meckel syndrome discovered on ultrasound during a 37 week amenorrhea pregnancy.

II. CASE REPORT

Patient aged 30 years, primiparous primigravida, without any notable pathological antecedent. She had consulted for the first time for pregnancy at 37 weeks of amenorrhea in labor. A fetal ultrasound was carried out, showing a progressive mono-fetal pregnancy with fetal malformations including: major hydrocephalus (Figure 1) + poly malformative renal (Figure 2) and cardiac syndrome associated with severe anamnios. A vaginal delivery of a female fetus, weight 2200g. The examination macroscopic found: at the level of the cephalic pole: retrognathism (Figure 3) and posterior encephalocele ; in the abdomen: hepato splenomegaly with ascites; in the limbs: polydactyly (Figure 4) on the 4 distal segments, clubfoot (Figure 5) and a curved aspect of the humerus ; examination of the spine and external genitals is normal. In the face of this poly malformative syndrome, the diagnosis of Meckel's syndrome was evoked.

III. DISCUSSION

➤ Definition

Meckel syndrome is a rare congenital poly malformative syndrome of autosomal recessive transmission, first described in 1822 in German literature. The Meckel syndrome is an inherited syndrome characterized by a set of congenital malformations affecting in particular the central nervous system and the kidneys. It is usually fatal shortly after birth [2].

➤ Epidemiology

Meckel syndrome affects 1 in 13,250 to 1,140,000 people worldwide. It is most common in Finland, where its prevalence at birth is 1 in 9,000 and the mutation frequency is 1% [3]. Three genes have been mapped: MKS1 on chromosome 17, MKS2 on chromosome 11, and MKS3 on chromosome 8.

➤ Clinic

Meckel syndrome is a monogenic disease characterized by a combination of renal cysts and other manifestations [4]: developmental abnormalities of the central nervous system (occipital encephalocele); polydactyly; dysplasia of the bile ducts and liver cysts. Meckel syndrome is generally defined by the triad: occipital encephalocele, cystic kidney dysplasia and polydactyly. Polydactyly is most often post-axial (6th finger), but can sometimes be pre-axial (duplication of the thumb). A curvature of the long bones of the limbs is present in 1 out of 6 cases. Other abnormalities may be present: cleft lip and palate, anophthalmia or microphthalmia, urethral atresia, heart and genital deformities.

➤ Diagnostics

Major criteria: Cystic kidney dysplasia is a mandatory criterion for diagnosis in association with a history [5-7]; minor criteria: hepatic fibrosis; occipital encephalocele; polydactyly; other central nervous system malformations: Dandy-Walker malformation and Arnold Chiari malformation.

➤ Antenatal diagnosis

Prenatal diagnosis can be made on the basis of an ultrasound image of intracranial anechoic cyst and/or an cranial malformation at the end of the first trimester or in the presence of abnormally large kidneys [8]. The other features of the syndrome can be detected later on ultrasound. Amniocentesis may reveal elevated levels of amniotic alpha-fetoprotein due to encephalocele [9]. Karyotype remains the best way to confirm the diagnosis. If the pregnancy is carried to term, the newborn dies in the perinatal period.

➤ *Evolution*

Meckel syndrome is lethal with an average survival of less than 24 hours. However Genuardi describes a case of Meckel's syndrome comprising polycystic kidneys, a Dandy-Walker, and postaxial polydactyly at baseline and surviving 43 months before dying of renal failure [10]. Genetic counseling aims to inform the parents of an affected individual that the risk of recurrence is 25% for subsequent pregnancies.

➤ *Differential diagnosis*

Trisomies 13 and 18 are eliminated in front of a normal karyotype [11]. Other poly malformative syndromes may pose greater diagnostic difficulties. Carpenter-Hunter syndrome combines encephalocele, renal cystic dysplasia, polydactyly, but also generalized bone lesions. Polydactyly is also found in Ellis von Creveld's syndrome, short rib polydactyly, Moon-Bardet-Biedl, holoprosencephaly-polydactyly (pseudo-trisomy 13). A large diagnostic assistance will be provided by isolating the Meckel syndrome gene.

➤ *Genetic counseling*

Meckel syndrome is autosomal recessive. The frequency of the Meckel syndrome gene in the general population is around 1/400. At present, it is still impossible to accurately screen for the Meckel syndrome gene. However, the recent localization of the responsible locus on chromosome 17 with three potentially involved genes shows that the search is close to the goal. This is why, in the absence of formally defined criteria for Meckel syndrome, it is essential to preserve fetal tissue for gene and molecular analysis that will allow an accurate diagnosis. Indeed, if in the case of an isolated Dandy Walker the genetic counselling must be reassuring, the risk of local recurrence being 1%, in case of Meckel syndrome with Dandy Walker this risk is 25% [12].

IV. CONCLUSION

Fetal abnormalities observed in Meckel-Gruber syndrome can be diagnosed by antenatal pregnancy ultrasound and medical termination of pregnancy and genetic counselling are offered. It is a lethal malformation of autosomal recessive transmission and can be detected as early as the first trimester. In countries with high rates of consanguineous marriages, caution should be exercised and genetic counselling should be offered;

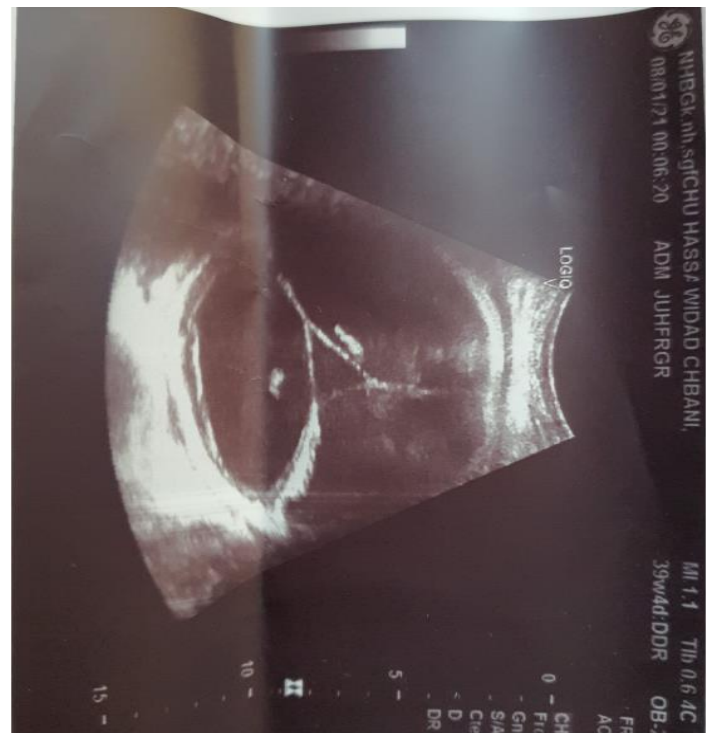


Figure 1: Aspect échographique d'une hydrocéphalie majeure

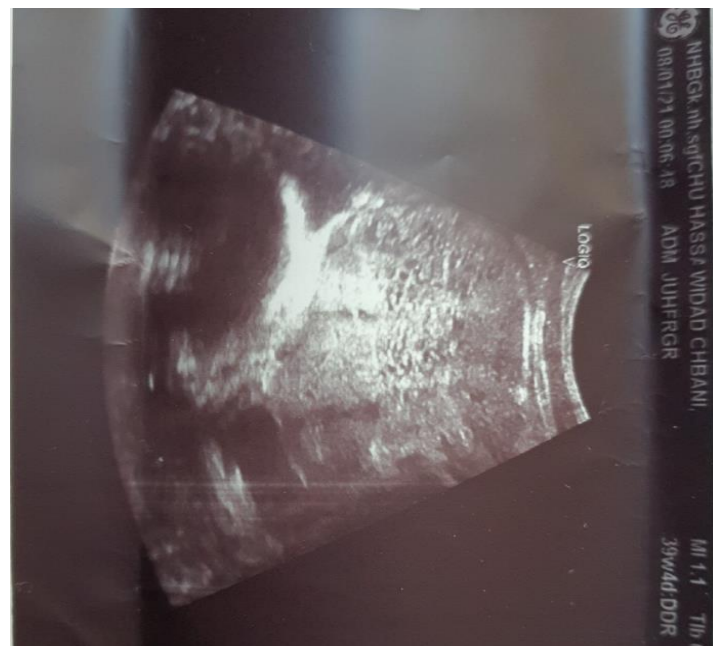


Figure 2: Aspect échographique de kystes rénaux

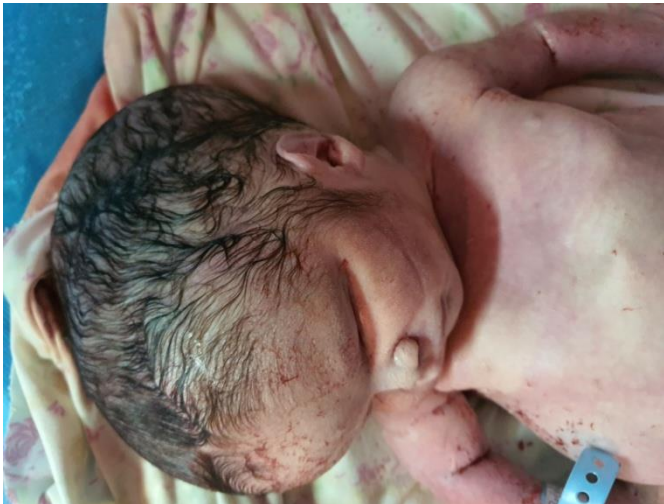

Figure 3: Aspect de rétrognatisme neonatal

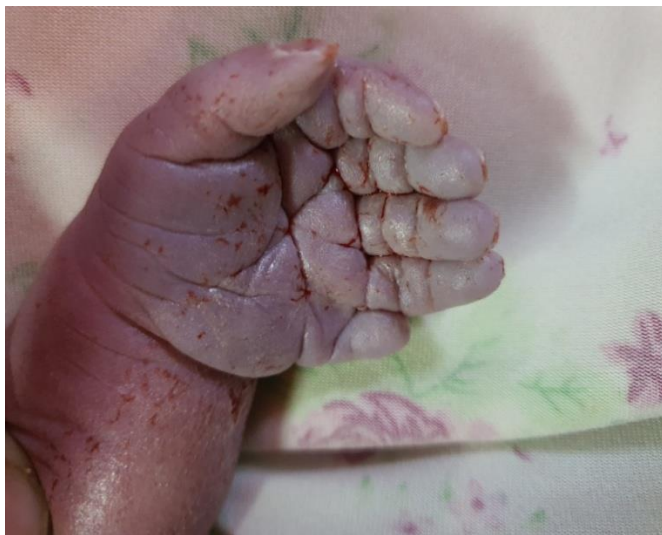

Figure 4: Polydactylie sur les 4 segments distaux

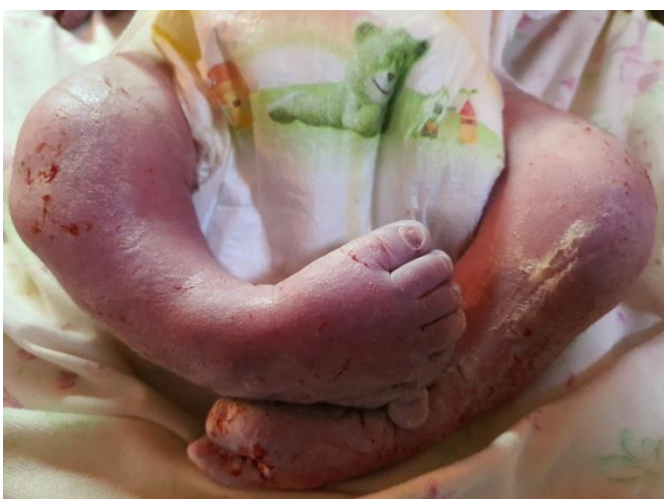

Figure 5: Aspect de pieds bots avec polydactylie

REFERENCES

- [1]. Opitz JM, Howe JJ. The Meckel syndrome (dysencephalia splanchnocystica, the Gruber syndrome). *Birth Defects*. 1969;5:167.
- [2]. Wright C, Healicon R, English C, et al. Meckel syndrome: what are the minimum diagnostic criteria? *J Med Genet*. 1994;31:482-485.
- [3]. Hsia YE, Bratu M, Herbordt A. Genetics of the Meckel syndrome (dysencephalia splanchnocystica). *Pediatrics*. 1971;48:237-247.
- [4]. Mecke S, Passarge E. Encephalocele, polycystic kidneys, and polydactyly as an autosomal recessive trait simulating certain other disorders: the Meckel syndrome. *Ann Genet*. 1971;14.
- [5]. Jha T, Bardhan J, Das B, Patra KK, Dhali B, Seth S. MeckelGruber syndrome: a rare clinical entity. *J Indian Med Assoc*. 2010; 108(9): 611-2. **PubMed | Google Scholar**
- [6]. Desai SR, Wader JV. Meckel Gruber Syndrome--a case report. *Indian J Pathol Microbiol*. 2004; 47(3): 430- 2. **PubMed | Google Scholar**
- [7]. Walsh M, Graupman P. Meckle Gruber syndrome in association with occipital meningocele. *Pediatr Neurosurg*. 2006; 42(5): 333-4. **PubMed | Google Scholar**
- [8]. Van Wymersch D, Favre R. Intérêt de l'échographie tridimensionnelle en obstétrique et gynécologie. *Réf Gynécol Obstét*. 1995; 31: 82-7. **PubMed | Google Scholar**
- [9]. Ickowicz V, Eurin D, Maugey-Laulom B, Didier F, Garel C, Gubler MC, et al. Meckel-Grüber syndrome: sonography and pathology. *Ultrasound Obstet Gynecol*. 2006; 27(3): 296-300. **PubMed | Google Scholar**
- [10]. Kheir AEM, Imam A, Omer IM, Hassan IMA, Elamin SA, Awadalla EA et al. Meckel-Gruber Syndrome: a rare and lethal anomaly. *Sudan J Paediatr*. 2012; 12(1):93- 96. **PubMed | Google Scholar**
- [11]. Alexiev BA, Lin X, Sun CC, Brenner DS. Meckel Gruber syndrome: pathologic manifestations, minimal diagnostic criteria, and differential diagnosis. *Arch Pathol Lab Med*. 2006; 130(8):1236-8. **PubMed | Google Scholar**
- [12]. Philip N, Mattei JF. Malformations congénitales: intérêt génétique et étiologique. Dans *Echographie des malformations fœtales*. Vigot Paris; 1990 :9-17. **Google Scholar**