

# Periodontal Treatment for Perforated Internal Root Resorption - Case Report

Dr. Sindhura. H<sup>1</sup>, Dr Harsha. R. H<sup>2</sup>, Dr Shilpa. R.H<sup>3</sup>, Dr. Gayatri Gundannavar<sup>4</sup>

<sup>1</sup>Reader, Department of Periodontology, Navodaya Dental College, Raichur.

<sup>2</sup>Professor, Department of Prosthodontics and Crown and Bridge, Navodaya Dental College, Raichur.

<sup>3</sup>Associate Professor, Department of oral Surgery and Trauma Center, MVJ Medical College and Research Hospital, Bangalore.

<sup>4</sup>Professor, Department of Periodontology, The Oxford Dental College. Bangalore.

**Abstract:- Internal root resorption is a pathological entity starting within the pulpal tissue in which pulp chamber or root canal, or both expand by resorbing the surrounding dentin. Internal root resorption is a rare entity but when it occurs, it mostly involves the permanent incisors. Clinically the first evidence of the lesion appears on crown portion as an emergence of a pink hue on tooth surface. Most cases of internal root resorption present no early clinical symptoms and it is diagnosed based on routine radiographic examination. Here we present a male patient with internal resorption of a 22 year old treated by a periodontal flap surgery along with a root canal management (RCT)**

**Keywords:- Internal Root Resorption, Gingivectomy, RCT, Flap Surgery.**

## I. INTRODUCTION

IR is being a pathological resorptive defect with foremost obliteration of intraradicular dentin, dentinal tubules alongside with middle and apical thirds of the canal walls due to clastic activities that arise as a physiologic or pathologic phenomenon. [1] It is considered as a rare case with prevalence of 2.16%, exclusively seen in permanent anterior as shown in fig 1.[2] Most commonly caries, trauma, anachoresis, extreme generation of heat during restorative procedures, Periodontal infections; resections of vital root, orthodontic treatment and fractured tooth are few etiologic factors responsible for IR.

It presents as a distinctive dystrophy of pulp that jeopardizes the usual tooth morphology. It is recurrently seen in cervical area involving the coronal aspect. The tooth presents as a pink spots. This pink spots are due to the inflammation associated with capillary proliferation. IR is called Pink tooth of Mummery, was named after anatomist "James Howard mummery". [3]

As patients are unaware of symptoms it may remain unnoticed for several years, but it there is any significant changes in pulpal inflammation or if there is an any communication of pulp tissue then patients might notice some discomfort and pain. Generally it can be determined on

a usual clinical examination and on periapical radiographs where an unusual resorption changes might be noticed. [4]

Radiographically, it presents as a uniform, round-to oval radiolucent within the pulp space. The boundaries are even and obviously distinct, with distortion of original root canal outline [5]

On diagnosing the internal root resorption, clinician formulates and assesses the prognosis of the tooth. When the tooth with a deemed restorable and with a reasonable prognosis root canal treatment is the choice of treatment. This allows eradicating the residual vital, apical tissue and necrotic pulpal tissue. Thereby reducing the activity of resorbing cells and by disinfecting and the diseased portion of the root.[6] In light of above facts, the present case report describes internal root resorption in relation to lower right lateral incisor.

## II. CASE REPORT

A male patient of 22 years visited Dept. of Periodontics with a chief complaint of swelling in relation to lower right tooth since 6 months. Patient noticed a swelling which gradually increased over a period of 3 months and noticed dull sort of pain since 3-4 days. After verifying the complete blood investigations which included investigations of Complete Blood Picture (CBP), Random Blood Sugar (RBS) the medical history was non-contributory. On intra oral evaluation the labial aspect of lower right lateral incisor revealed a solitary sessile reddish growth involving the marginal gingival and the interdental papilla, of approximately 5x6mm.(fig 2) It showed spongy consistency, easily retractable; tender on palpation, bleeding on probing with exudation was noticed. 5-mm of periodontal pocket was present on the labial phase of incisor. A pink discoloration was present on the lingual aspect of lower right lateral incisor (fig 3). The patients had a poor oral hygiene. The tooth otherwise didn't respond to thermal and electric pulp testing while the adjacent teeth responded within normal limits. Periapical radiograph revealed a large confined, comparatively oval radiolucent lesion in the coronal and cervical areas of the pulp chamber in the lower right lateral incisor (fig 4). Based on clinical and radiographic investigation an internal root resorption was diagnosed. Through SRP was performed and after 3 weeks patient

was recalled and further evaluation was carried out. The region was administered with local anesthesia, mental nerve block for the gingivectomy with respect to 42(fig 5). The swelling was completely excised.

The patient was recalled after 2 week and the site showed an uneventful healing (fig 6). Patient was subjected for the access flap surgery. 15no. surgical blade was used and a crevicular incision was given (fig 7). A full thickness mucoperiosteal flap was reflected and the surgical site was debrided. After debridement a resorption defect was seen on labial cervical aspect of 42 (fig 8). An access opening was achieved on the lingual aspect of the crown after the tooth was isolated (fig 9). Resorption defect was restored by GIC first by blocking the canal with suitable reamer (fig 10) and the periapical radiograph was taken (fig 11) and Root canal treatment was done (fig 12). The flap was approximated and sutured (fig 13). Periodontal pack was applied and the post operative instructions were given. After 3 week's patient was recalled (fig14) and followed up for 6 months (fig 15) with no evidence of further resorption.

### III. DISCUSSION

Resorption is defined as a condition associated with either a physiologic or a pathologic process resulting in loss of dentin, cementum or bone this is in accordance with Glossary of American Association of Endodontists. Physiologic resorption is usually noticed in primary teeth that leads in to their exfoliation and allows eruption of permanent successors. Pathologic resorption can occur due to excessive orthodontic tooth movement, traumatic injuries, long standing infections of the pulp or periodontal tissues. If this left untreated can lead to premature loss of the affected teeth.<sup>[7]</sup> Internal inflammatory root resorption is mostly seen during the fourth and fifth decades with male predilection which is an insidious pathological process, occurs within the pulp space and can affect both the primary and secondary dentition, but it often observed in permanent anterior teeth. According to Andreasen he has classified three types of resorption following trauma: surface resorption, replacement root resorption and inflammatory root resorption.<sup>[8]</sup> The exact etiology of internal resorption still remains as unknown; however, due to chronic inflammation within the coronal pulp tissues and loss of predentin following traumatic injuries have been avowed as the key reasons for the commencement and progression of internal resorption.<sup>[9]</sup> It is commonly described as an oval shaped swelling within the pulp chamber and frequently remains as asymptomatic lesion and becomes more evident by Periapical radiographs. When diagnosed, immediate elimination of the contributing agent must be considered, aiming to seize the cellular activity accountable for the resorptive activity.<sup>[10]</sup> Therefore accurate diagnosis and treatment is extremely significant in order to prevent the further progression of activity. The success or failure of therapy should be followed clinically and by radiographic examination. A successful treatment of an internal resorption therapy includes non surgical, recalcification, remineralization with calcium hydroxide preparation and

surgical procedures. As a result it is a dilemma for many clinicians whether to treat a tooth with questionable prognosis endodontically or extract it and subsequently replace with an implant.

The current case report showed the methodological diagnosis of internal root resorption and appropriate treatment provided to restore the tooth instead of extraction and replacement by prosthesis or osseointegrated implant.

### IV. FIGURES

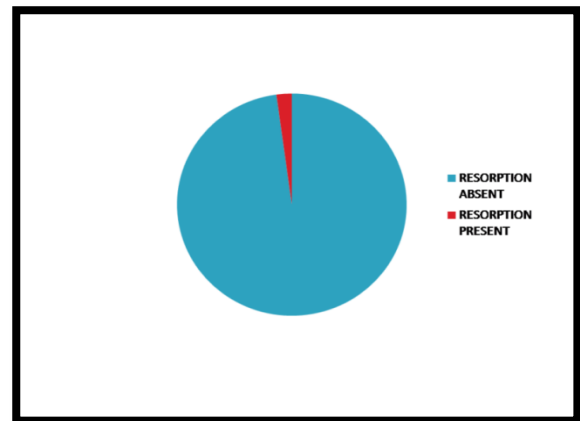


FIG 1 PREVALENCE OF INTERNAL ROOT RESORPTION IN PERMANENT ANTERIOR TEETH.

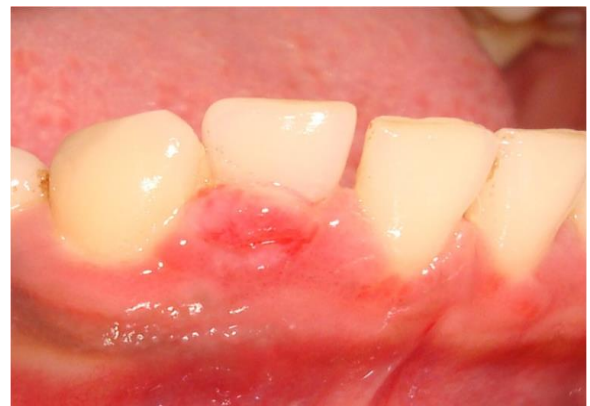

FIG 2:- PREOPERATIVE PHOTOGRAPHS

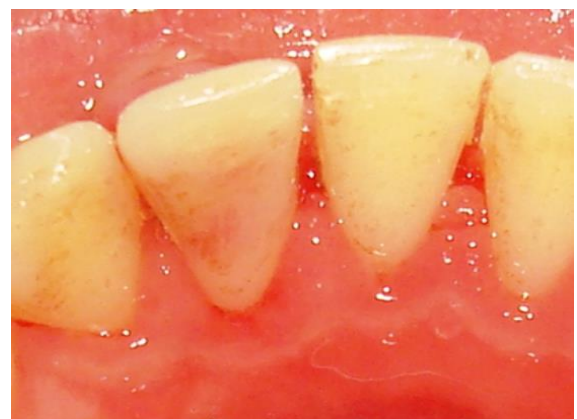

FIG 3:- PREOPERATIVE PHOTOGRAPHS WITH PINK DISCOLORATION SEEN ON THE LINGUAL ASPECT.

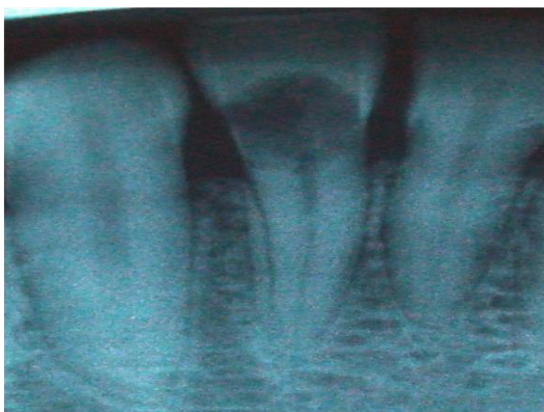

FIG 4:- INTRA ORAL PERIAPICAL RADIOGRAPH

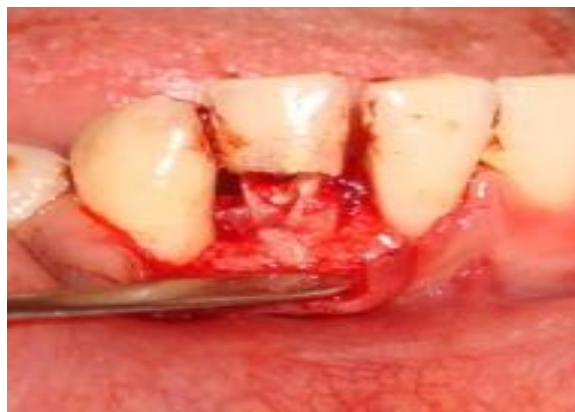

FIG 8:- RESORPTION DEFECT SEEN ON THE LABIAL CERVICAL ASPECT OF 42

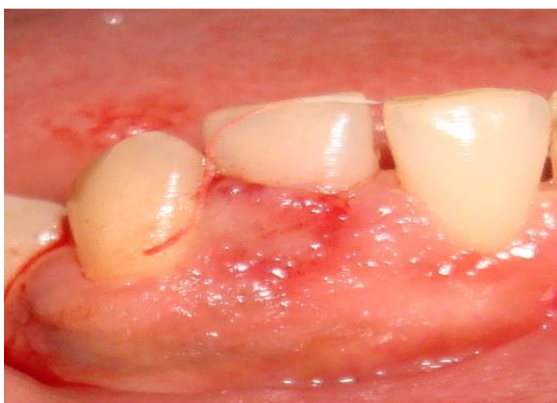

FIG 5:- EXCISION OF GINGIVAL TISSUE

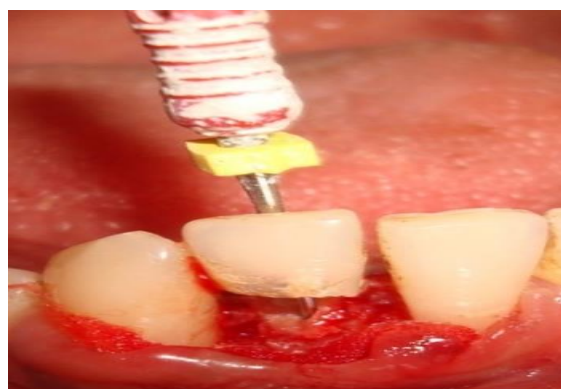

FIG 9:- CANAL BLOCKED WITH REAMER

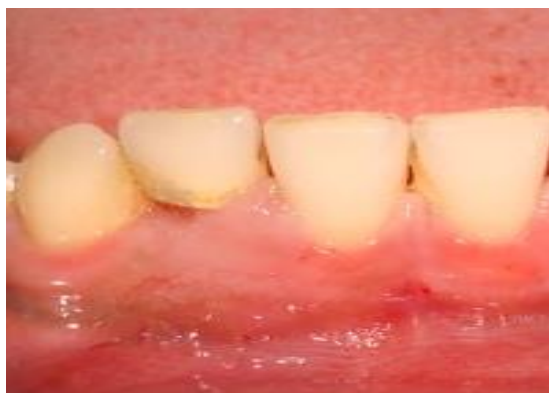

FIG 6:- 2 WEEKS POSTOPERATIVE PHOTOGRAPHS AFTER GINGIVAL EXCISION

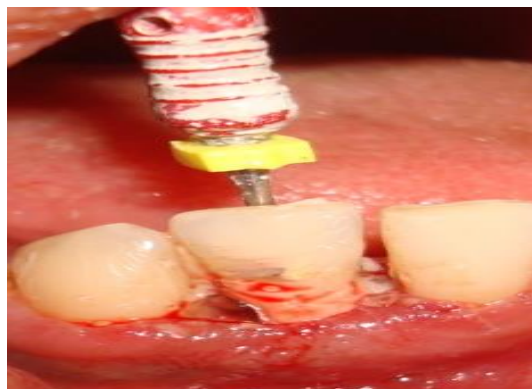


FIG 10:- RESORPTION DEFECT RESTORED WITH GIC IN ORDER TO COMPLETE THE ROOT CANAL TREATMENT.

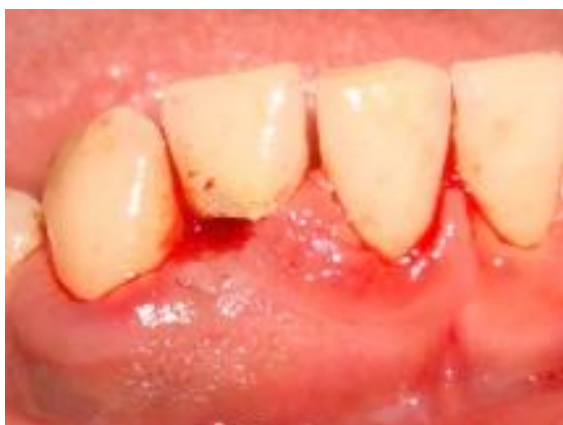

FIG 7:- CREVICULAR INCISION PLACED

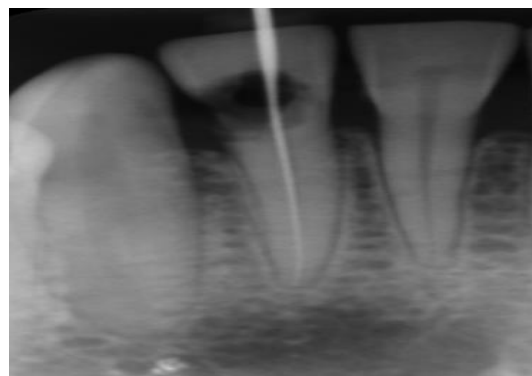


FIG 11:- INTRA ORAL PERIAPICAL RADIOGRAPH



**REFERENCES**

- [1]. Kothari HJ, Kumar R. Endodontic management of a mandibular second premolar with perforating internal resorption by using MTA and cone beam computed tomography as a diagnostic aid. *J Conserv Dent* 2013;16:380-4.
- [2]. Araújo LCG, Lins CV, Lima GA, Travassos RC, Lins CS. A Study of prevalence of internal resorption in periapical radiography of anteriors permanent tooth. *Int J Morphol* 2009;27:227-230.
- [3]. Patel S, Ricucci D, Durak C, Tay F. Internal root resorption: a review. *J Endod*. 2010;36:1107-21.
- [4]. Egea JJS, Cosano LC, Gonzalez JM, Ezpeleta LA, Frías FJL. Green discoloration of the crown after internal root resorption treatment with grey mineral trioxide aggregate (MTA). *J Clin Exp Dent*.2011;3:404-7.
- [5]. Meire M, De Moor R. Mineral Trioxide Aggregate Repair of a Perforating Internal Resorption in a Mandibular Molar. *J Endod* 2008;34:220-3.
- [6]. Ozer YS. Diagnosis and Treatment Modalities of Internal and External Cervical Root Resorption: Review of the literature with Case Report. *Int Dent Res* 2011;1:32-37.
- [7]. Fernandes M, de Ataíde I, Wagle R. Tooth resorption part I - pathogenesis and case series of internal resorption. *J Conserv Dent*2013;16:4-8.
- [8]. Moule AJ, Moule CA. The endodontic management of traumatized permanent anterior teeth: A Review. *Aust Dent J* 2007;52:122-37.
- [9]. Ashouri R, Rekabi AR, Parirokh M. Surgical intervention for treating an extensive internal resorption with unfavorable crown-to-root ratio. *J Conserv Dent* 2012;15:388-91.
- [10]. Jacobovitz M, de Lima RK. Treatment of inflammatory internal root resorption with mineral trioxide aggregate: a case report. *Int Endod J* 2008;41:905-12.

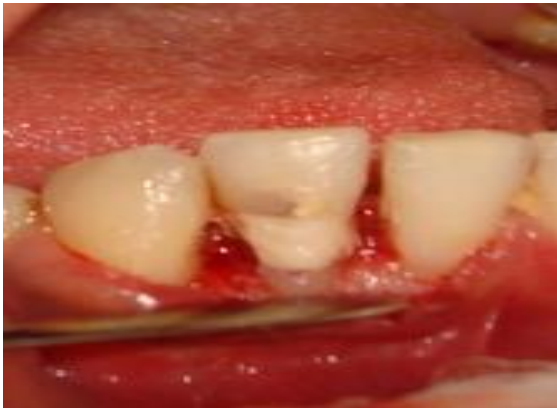

FIG 12:- THE RESTORATION WAS SMOOTHENED AND ROOT CANAL TREATMENT WAS CARRIED OUT.

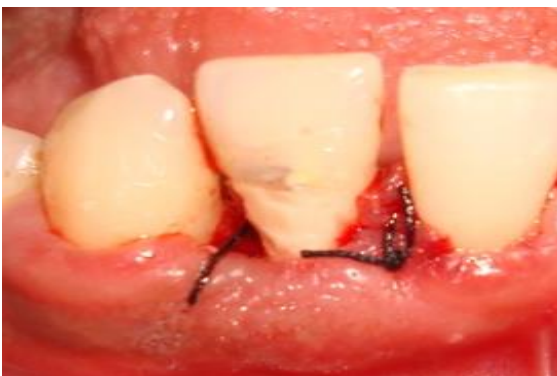

FIG 13:- SUTURES PLACED

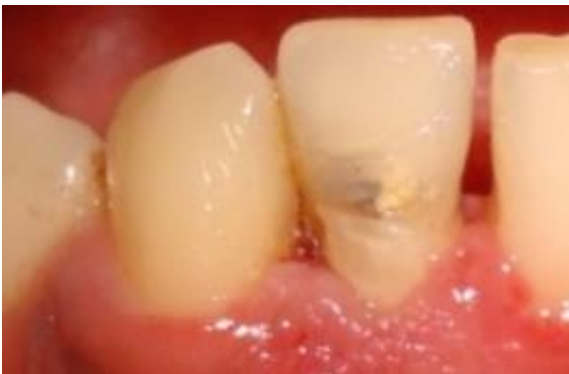

FIG 14:- 3 WEEKS POST OPERATIVE PHOTOGRAPHS

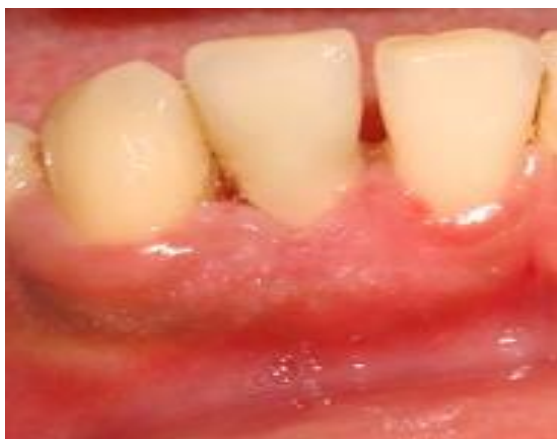

FIG 15:- 6 MONTHS FOLLOW UP