

# Case Report

## Bilateral Ectatic Corneas Post Myopic Laser-Assisted in Situ Keratomileusis Refractive Surgery

Emad Mahmoud, FRCS  
Cork University hospital  
Cork, Ireland.

Sinead Fenton  
Cork University hospital  
Cork, Ireland.

### Abstract: -

### Purpose

Herein We report a case of bilateral corneal ectasia following myopic Laser in situ keratomileusis refractive surgery.

### Methods

A case report, retrospective study.

### Results

40-years male presented to Cork university hospital, Ireland complaining initially with bilateral blurry and distorted vision since few months ago. He had myopia -5 dioptre wearing glasses for many years and he decided to take his glasses off and corrected his myopia by LASIK (Laser assisted in-situ Keratomileusis) for 5 years ago in Syria. No medical or family history of eye disease.

On biomicroscopy examination reveals normal lid, white conjunctiva, normal lacrimal apparatus, bilateral corneal flaps are intact, no flap complications or corneal infection, bilateral irregular contour of the cornea, thinning the cornea inferiorly, anterior chamber was deep and quiet, regular iris configuration, bilateral clear red reflex and bilateral clear natural lenses.

Dilated fundoscopic examination showed a myopic sign such as bilateral peripheral choro-retinal degeneration, peripapillary atrophy, and typical type of lattice degenerations at supero-temporal quadrants of both eyes. He had healthy optic nerve, cup disc ratio 0.3 bilaterally, retina flat and healthy dry macula.

He had a Scissors reflex on retinoscopy, Munson sign (increased angulation of lower lid margin at down gaze due to protrusion of the cornea), Oil droplet reflex of Charleaux with direct ophthalmoscope, he had irregular astigmatism with inability to correct the patient to 20/20 with manifest refraction.

Central Corneal thickness was checked by Pachymetry and showed bilateral thin cornea 452 microns right eye and 443 microns left eye. Corneal topography revealed bilateral inferior steepening of the cornea, superior flattening and irregular astigmatism. He had 6.3 D. at right eye and 7.6 D. at left eye.

Anterior segment optical coherence (AS-OCT) detected there was change of central corneal epithelial profile thickness. It was typical case of corneal ectasia post Lasik.

### Conclusions

Corneal ectasia is a very serious and devastating visual complication following refractive surgeries.

**Keywords;-** Lasik, Corneal ectasia, corneal topography, optical coherence tomography, keratoplasty.

## I. INTRODUCTION

Corneal ectasia is rare, but it is the most catastrophic visual complication following Laser assisted in-Situ keratomileusis (LASIK) and photorefractive keratectomy (PRK). The majority of cases occurred after Lasik (96%) and only 4% occurred after PRK. it is a progressive complication associated with increase in myopia, irregular astigmatism and asymmetrical inferior steepening of the cornea by topographic analysis<sup>1,2</sup>. The main aspect is Careful preoperative assessment for patients before refractive surgeries to prevent corneal ectasia.

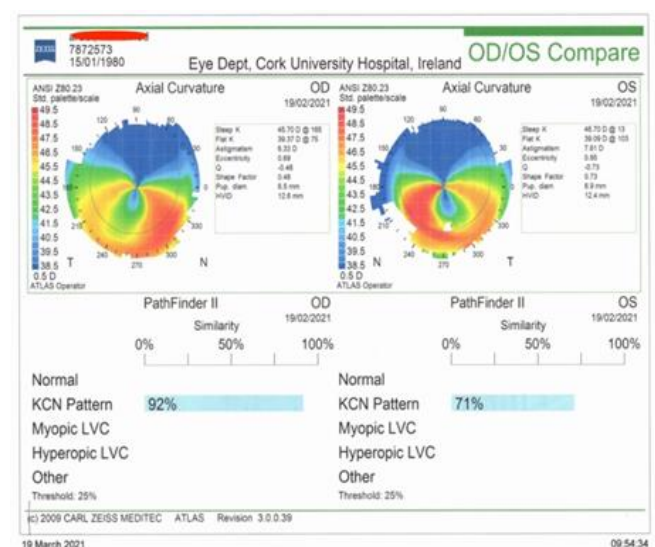


Figure 1 bilateral Corneal ectasia post myopic Lasik

## II. METHODS

Ectatic cornea can be diagnosed clinically and corneal topography analysis.

Early clinical detection of corneal ectasia after refractive surgery require a high clinical suspect. The first signs are often myopia progression and astigmatism with blurry and distorted vision. More advanced signs increase of irregular astigmatism and accompanied by corneal thinning and bulging especially inferiorly<sup>3</sup> and inability to correct the patient's error to 20/20.

Corneal Topographic changes are starting subtle and progress more over time. Inferior steeping of the cornea, flattening superiorly, and irregular astigmatism.

Anterior segment optical coherence (AST-OCT) by studying of the corneal epithelial thickness profile may improving detection early cornea ectasia with interpretation of Corneal topography.

## III. DISCUSSION

Laser assisted in-situ keratomileusis surgery is the process of reshaping cornea using excimer laser beam. it used for myopia, hyperopia, and astigmatism correction by creating very thin protective flap and lifted to let second laser ablation to correct the vision. It is considered safe and effective for use in appropriately selected patients. However, Changes in histopathology and biomechanics of the cornea that put the patient at risk for corneal ectasia post refractive surgery<sup>4</sup>.

In the majority of cases of cornea ectasia, there have predisposing factors making them more likely to develop it such as thicker corneal flap, thin cornea thickness, excessive laser ablation, irregular corneal thickness, thin residual stromal bed thickness (RSB) and early keratoconus or fruste keratoconus resulting in a loss of ability to maintain corneal integrity.

In the native cornea the anterior 40% of the cornea has a higher Cohesive tensile strength than the posterior 60% perhaps due to higher density of keratocytes in the anterior 10% of the stroma<sup>4,5,6</sup> Dr Randleman developed ectasia "Risk assessment for post-Lasik" abnormal topography stands alone as something that can exclude people<sup>6</sup>. if a patient has a topographic pattern that indicates keratoconus, pellucid marginal degeneration or form fruste keratoconus, then they should absolutely be excluded from Lasik. Pachymetry is another factor is preserving enough residual stromal bed. Traditionally, the accepted range as has been 200-325 microns, but each cornea it is different, and no one knows what is exactly number to avoid ectatic cornea.

There is another red flag factor such as asymmetry between the eyes for example astigmatism 90 degree in one eye and at 180 degree in the other eye may be a sign that one eye is progressing towards corneal ectasia.

One histopathologic study of 12 ectatic corneas after Lasik that underwent keratoplasty .The specimens were examined under microscopy and transmission electron microscopy (TEM).It showed epithelial hypoplasia and hyperplasia, bowman's layer breaks, thinned residual stromal bed, hypocellular stromal scarring, artifactually larger interlamellar clefts within ectatic area<sup>7</sup>.TEM showed thinning of the collagen lamellae and loss of the total number of the lamella at residual stromal bed .

Also, LASIK may reduce biomechanics of the cornea by decreasing of keratocytes density at centre of the cornea thus reducing the tensile strength of remaining cornea tissue. This leading to corneal instability and weakness.

### Management of post-Lasik ectasia

- Glasses: mild cases of corneal ectasia can be treated with spectacles, but it is usually insufficient as the majority of patients have irregular astigmatism.
- Rigid Gas Permeable contact lenses: they are the main treatment options for cornea ectasia for irregular astigmatism but, there is some risk of treatment failure due to discomfort and intolerance, inability to fit ectatic cornea, or poor visual outcome.
- Scleral contact lenses: larger diameters of scleral C.L.can have very therapeutic value. These lenses more comfortable and can fit over a larger surface and provide a larger pocket of tears neutralizing cornea irregularities.
- Corneal Cross-Linking (CXL); It is minimally invasive procedure to halt ectatic cornea progression.It is useful to treat early cases of cornea ectasia.
- Intrastromal corneal ring segments (INTACS) by inserting extra rings into the deep cornea at the corneal mid-periphery to change corneal shape and curvature.
- Penetrating keratoplasty (PKP) and Deep Lamellar keratoplasty (DALK) are the last options when all previous treatment fails. Both of them have intraoperative, early and post-operative surgical complications.

## IV. CONCLUSION

Cornea ectasia post Lasik is rare, but it is threatening visual problem encountered after refractive procedures. Very careful Preoperative assessment of patients clinically, topographic analysis and AS-OCT are essential to reduce risk of corneal ectasia after refractive surgery. However, there are many visual rehabilitation options such as glasses, Rigid CL, Scleral CL, cross-linkage, intrastromal ring segments, deep lamellar (DALK) and penetrating keratoplasty (PKP).

## REFERENCES

- [1]. Krachmer JHMM, HollandEJ. Cornea. Elsevier, Mosby;2010.
- [2]. Randleman JB, Russell B, Ward MA, Thompson KP, Stulting RD. Risk factor and prognosis for corneal ectasia after Lasik.ophthalmology.2003;110(2):267-75.
- [3]. Randleman JB, woodward MA chapter 4: Evaluation and diagnosis of ectas\*a. In: Hafezi F, Randleman JB, editors. Corneal collagen cross-linking. Slack incorporated;New Jersey: 2013.PP31-8

- [4]. Bromley JG,Randleman JB.treatment strategies for corneal ectasia.Current opinion in ophthalmology.2010;21(4):255-8
- [5]. Schmack I,Dawson DG,McCarey BE ,waring GO,3<sup>rd</sup> ,Grossniklaus HE,Edelhauser HF.Cohesive tensile strength of human LASIK wounds with histologic,ultrastructural,and clinical correlations.Journal of refractive surgery (Thorofare,NJ :1995) 2005;21(5):433-45
- [6]. Randleman JB, Dawson DG, Grossniklaus HE, McCarey BE, Edelhauser HF: Depth-dependent cohesive tensile strength in human donor corneas; implications for refractive surgery. Journal of refractive surgery (Thorofare, NJ:1995) 2008;24(1) S85-9
- [7]. Dawson DG, Randleman JB,Grossniklaus HE,O'Brien TP, Dubovy,Schmack I,et al. Corneal ectasia after excimer laser kerato refractive surgery; histopathology, ultrastructure, and pathophysiology.Ophthalmology.2008;115(12):2181-91.e1