

# Primary Non-Hodgkin Lymphoma of Breast: A Rare Case Report and Review of Literature

Diptajit Paul<sup>1</sup>, Tarangini Yadav<sup>1</sup>, Anil Kumar Dhull<sup>2</sup>, Vivek Kaushal<sup>3</sup>

<sup>1</sup>. Junior Resident

<sup>2</sup>. Assistant Professor

<sup>3</sup>. Senior Professor and Head of Department

Department of Radiation Oncology, Pt. B. D. Sharma PGIMS, Rohtak

**Corresponding author:** Diptajit Paul, Final Year Resident, Department of Radiation Oncology, Pt. B. D. Sharma PGIMS, Rohtak, Haryana, India,

**Abstract:-** Primary breast lymphoma, a rare entity, accounts for a few breast malignancies. Establishing a careful histopathological diagnosis and prompt treatment planning based on multidisciplinary approach is of cardinal value. Combination chemotherapy is the mainstay of treatment as in other lymphoma, but role of radiation therapy and surgery has also been studied thoroughly. Here we discussed the clinico-pathological features of primary non-Hodgkin lymphoma in a young female treated by R-CHOP regimen. Despite getting partial response on chemotherapy, patient was died after 1-year of initial diagnosis.

**Keywords:-** Primary Breast Lymphoma, Non-Hodgkin Lymphoma, R-CHOP Chemotherapy, Radiation Therapy.

## I. INTRODUCTION

Extra-nodal lymphoma is a type of tumor that are extremely rare in breast. Clinically these tumors are nearly indistinguishable from breast carcinoma primarily, but have a more locally aggressive form. Here we reported a case of primary breast lymphoma in a young female aimed to treat by combination chemotherapy.

## II. CASE SUMMARY

A 23-years young married, nulliparous, woman presented with painless lump in left breast of 6-months duration, which was insidious onset progressive involving whole of breast, which is not associated with discharge and had no relieving or aggravating factors. Patient had no associated history of weight loss, headache, backache, breathlessness or lump in opposite breast. She was vegetarian by diet & non-smoker, non-alcoholic and diagnosed case of HIV-AIDS, receiving ART for 2-years duration.

General physical and systemic examination was normal. Local examination revealed 12.0 × 10.0 cm growth involving all four quadrants of left breast which was ulcerative, firm, non-tender with retracted nipple (figure 1). In right axillary region there was presence of 2.0 × 2.0 cm single, firm, immobile, non-tender lymph node.

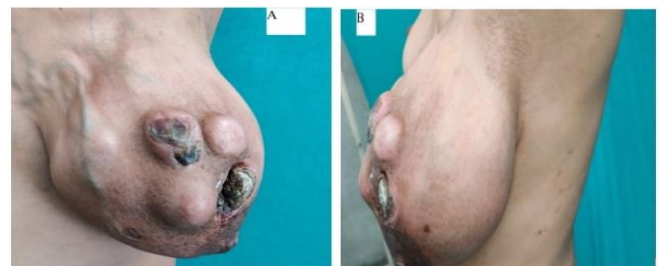

Figure 1: Pre-treatment clinical photograph showing hugely enlarged left breast mass having nodular pattern with necrosis in some places (nipple intact) and overlying prominent, tortuous superficial veins; (A) front view, (B) left lateral view.

Chest X-ray revealed no evidence pulmonary metastasis. CECT chest revealed heterogeneously enhancing mass lesion measuring 18.7 × 10.6 × 18.7 cm occupying whole of left breast and lesion axillary lymph node largest measuring up to 11.5 mm in short axis on left side and 12 mm in short axis on right side respectively. Whole body PET-CT scan (figure 2) revealed lesion of size 13.0 × 10.0 cm involving left breast parenchyma (SUVmax 14.0) abutting underlying chest wall along with lymph node of size 1.3 × 1.5 cm at right axillary region level I-III (SUVmax 4.9). Tru-cut biopsy from breast mass revealed malignant small round cell tumor. The neoplastic cells illustrated wide spread positivity for cluster differentiation 20 (CD 20), CD 19, CD 10 and B-cell lymphoma 6 protein (BCL 6) immunohistochemical (IHC) stain. The histopathological appearance and IHC markers confirms it to be a case peripheral B-cell non Hodgkin lymphoma favouring diffuse large B-cell lymphoma (figure 3).

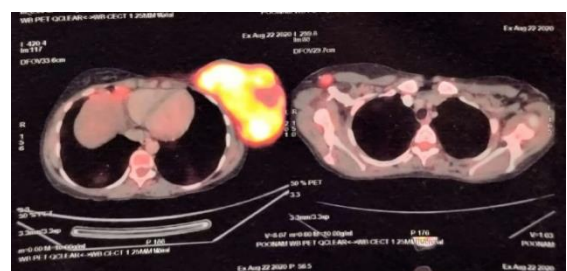


Figure 2: PET scan showing large mass (13 × 10 cm) with high FDG avidity (SUVmax 14.0) in left breast

As lesion was initially unresectable, patient was given 6-courses of combination chemotherapy with 3-weekly R-CHOP (rituximab 375 mg/m<sup>2</sup>, cyclophosphamide 750 mg/m<sup>2</sup>, doxorubicin 40 mg/m<sup>2</sup>, vincristine 1.4 mg/m<sup>2</sup> and tablet prednisolone 100 mg per oral day 1 to day 5) regimen. Although lesion size regressed, disease still persisted indicating partial response to chemotherapy. Patient was advised for local radiotherapy but was refused for further treatment. Patient condition deteriorated gradually and after a follow-up period of 1-year, patient expired.

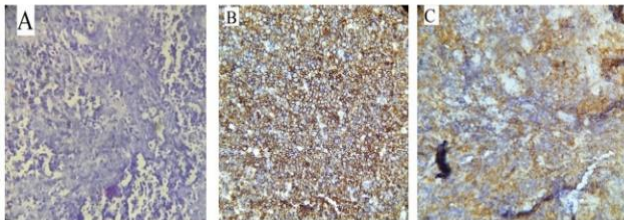


Figure 3: Photomicrographs (A): Hematoxylin-Eosin (H&E) stain, original magnification  $\times 10$ , showing small round blue malignant cells; (B): IHC stain, magnification  $\times 20$ , showing wide spread positivity of tumor cell for CD 20; (C): IHC stain, magnification  $\times 10$ , showing tumor cell positivity for CD10.

### III. DISCUSSION

Non-Hodgkin lymphoma as a primary tumour in female breast (Primary breast lymphoma or PBL) is a rare entity constituting approximately 0.5% of malignant breast neoplasms and around 1.6% of extranodal lymphoma.<sup>1</sup> Relatively small amount of lymphoid tissue in the breast accounts for the rare entity of lymphoma in breast whether it is Hodgkin or not and primary or secondary. However, there is an increasing trend of breast lymphoma, especially in women younger than 50 years as described in literature.<sup>2</sup> Association of breast lymphoma with HIV infection is well known and breast mass in HIV infected patients should be suspected for lymphoma as differential diagnosis.<sup>3</sup> It is also to mention that treatment of breast lymphoma in HIV infected patient should be more aggressive and should continue along with ART. Since its initial defining criteria described by Wiseman and Liao in 1972, primary breast lymphoma is clearly distinguished from secondary lymphoma, a more common disease entity.<sup>4</sup> Morphologically, both primary and secondary lymphoma present as painless, large breast mass indistinguishable from breast carcinoma. Normally, PBL lesions are solitary and larger; in contrast to multiple, small lesions of secondary lymphoma infiltration. In both cases, involvement of right breast is somehow more common with a right to left ratio of 3:2.<sup>5</sup>

Primary breast lymphoma, usually presenting as large breast swelling must be distinguished from other common causes of breast mass like carcinoma, fibro-adenoma, mammary dysplasia, sarcoma, breast abscess and acute mastitis. Pain, associated fever and other signs of infection are associated with breast abscess and acute mastitis. Breast lymphomas are usually larger than other malignant and benign tumours of breast. Moreover, skin involvement is less

common in lymphoma. However, tissue diagnosis is must to reach at a conclusion. Imaging is of little value to differentiate breast lymphoma and final diagnosis mostly rely on cytological & histopathologic examination and immunohistochemistry (IHC) evaluation. Cytology is frequently used as an initial tissue diagnosis tool, but due to paucity of its ability to differentiate lymphoid cells from reactive lymphocytes; biopsy is more preferred approach. Small blue round tumour cells in background of normal breast parenchyma is considered to be diagnostic of breast lymphoma with positivity for definite lymphoma markers like CD 20. Proper lymphoma subtyping is also essential for management approach as different chemotherapy regimens act better in different subtypes. Overall, diffuse large B-cell lymphoma is commonest subtype in literature review, others being T-cell lymphoma, Burkitt lymphoma and MALToma (mucosa-associated lymphoid tissue lymphoma).<sup>6</sup> As like in other lymphomas, whole body PET scan have great values in clinical staging of breast lymphoma and also to guess the treatment outcome based on extension of disease at initial presentation.

Although, breast lymphoma mimicking breast carcinoma in both clinical and radiological aspect, treatment guideline is completely different, special mention to avoid mastectomy or other surgical intervention appropriate for breast carcinoma. Breast lymphoma should be treated like lymphoma in other body parts and management plan should be based on staging (Ann Arbor system) & extent of disease, histological subtypes, general condition of patient and modalities available. Since lymphoma is both chemo- and radiosensitive; chemotherapy, radiation therapy or combination of both (sequentially preferred) can be given to treat breast lymphoma. Chemotherapy is considered for extensive disease burden. Regimens of chemotherapy is decided on lymphoma subtype and is similar to other lymphomas. Combination chemotherapy with cyclophosphamide, vincristine, doxorubicin and prednisolone (CHOP regimen) was explored in most of the case reports with satisfactory outcome.<sup>7</sup> Radiotherapy is mostly given in relatively small, single lesion to avoid systemic toxicity of chemotherapy and in recurrent or residual disease post-chemotherapy settings; newer techniques like involved field radiation therapy (IFRT) or elective field radiation therapy (EFRT) are preferred.<sup>8</sup> In some case reports of mature B cell lymphoma, surgery of breast lesion had down-staged the disease, allowing chemotherapy doses to be reduced.<sup>9</sup> Addition of rituximab to CHOP regimen in CD 20 positive tumours showed favourable outcome with less incidence of distant relapse and good loco-regional control.<sup>10</sup> Overall survival of breast lymphoma is variable with a 5-year survival rate approximately 40%.<sup>11</sup> Histologic subtype and clinical stage are the most important determinant of outcome.

Our patient's lesion fit the criteria for a primary breast lymphoma as there were no extra-mammary sites of involvement other than the contralateral lymph-nodes. In view of DLBCL subtypes, our own approach was to use the combination chemotherapy of R-CHOP regimen with partial response. Despite getting partial response in chemotherapy, patient did not survive a long time. This case report

demonstrates the need of adding radiation therapy in treatment approach to achieve a complete response in large, aggressive breast lymphoma.

#### IV. CONCLUSION

The oddity of primary breast lymphoma in clinical practice makes it prime diagnosis very unlikely. Despite mimicking breast carcinoma initially, few specific signs discussed already should arouse the suspicion of lymphoma and early diagnosis and prompt start of treatment may completely heal these subsets of extra-nodal lymphoma. Our presentation shows the aggressiveness of primary breast lymphoma and utmost need of combination modality treatment for radical cure. More case reports and case series in future will guide standard of therapy in these patients.

#### REFERENCES

- [1]. Ishizuka Y, Horimoto Y, Fujimura J, Ogata K, Murakami F, Onagi H et al. Primary breast non-Hodgkin's lymphoma in a 14-year-old girl: a case report. *Surgical case reports*. 2020 Dec; 6:1-5.
- [2]. Thomas A, Link BK, Altekruze S, Romitti PA, Schroeder MC. Primary breast lymphoma in the United States: 1975–2013. *JNCI: Journal of the National Cancer Institute*. 2017 Jun 1;109(6).
- [3]. Akinwande OK, Paley R. Primary breast lymphoma: a consideration in an HIV patient when a mass is discovered by screening mammography: a case report. *Cases journal*. 2008 Dec;1(1):1-4.
- [4]. Wiseman C, Liao KT. Primary lymphoma of the breast. *Cancer*. 1972 Jun;29(6):1705-12.
- [5]. Marinopoulos S, Safioleas P, Skorda L, Vassilopoulou E, Zagouri F, Sotiropoulou M et al. Breast lymphoma in a patient with B-cell Non Hodgkin Lymphoma: A case report study. *International journal of surgery case reports*. 2017 Jan 1; 40:1-5.
- [6]. DiPiro PJ, Lester S, Meyer JE, Denison CM, Takvorian T. Non-Hodgkin Lymphoma of the Breast: Clinical and Radiologic Presentations. *The Breast Journal*. 1996 Nov;2(6):380-4.
- [7]. Mohamed KE, Ali RA. Primary breast lymphoma: a case report and review of the literature. *Clinics and practice*. 2017 Jun;7(3):99-100.
- [8]. Lee KC, Lee SH, Sung K, Ahn SH, Choi J, Lee SH et al. A case of primary breast diffuse large B-cell lymphoma treated with chemotherapy followed by elective field radiation therapy: a brief treatment pattern review from a radiation oncologist's point of view. *Case reports in oncological medicine*. 2015 Jul 13;2015.
- [9]. Jennings WC, Baker RS, Murray SS, Howard CA, Parker DE, Peabody LF et al. Primary breast lymphoma: the role of mastectomy and the importance of lymph node status. *Annals of surgery*. 2007 May;245(5):784.
- [10]. Avilés A, Castañeda C, Neri N, Cleto S, Nambo MJ. Rituximab and dose dense chemotherapy in primary breast lymphoma. *Haematologica*. 2007 Aug 1;92(8):1147-8.
- [11]. Lyons JA, Myles J, Pohlman B, Macklis RM, Crowe J, Crownover RL. Treatment and prognosis of primary breast lymphoma: a review of 13 cases. *American journal of clinical oncology*. 2000 Aug 1;23(4):334-6.